The Incidental Liver Lesion: Tips for Characterizing and Managing the Spectrum of Benign Liver Tumors

Jonathan Kruskal, MD PhD

Robert A. Kane, MD

When faced with one or more incompletely characterized masses, as the CT scan image on left demonstrates, what additional imaging is necessary, if any, to confidently assign a "***benign-leave alone***" status to each tumor? This exhibit describes the imaging characteristics of the spectrum of benign hepatic tumors that may be encountered.

The above image shows an incidentally detected cyst, hemangioma and an adenoma.

- In the liver, common tumors occur commonly, and different benign tumors coexist.
- History, demographics, serology and relevant biochemistry are helpful.
- Many benign tumors have overlapping imaging features; these features are often non-specific and may be “atypical”.
- Benign liver tumors are classified according to their cell of origin into tumors of *hepatocellular, cholangiocellular or mesenchymal origin*.
- To be comprehensive, this exhibit also includes a number of pseudotumors & other tumor-like conditions that occur in the liver.

Tumors of Hepatocellular origin

- Adenoma
- Nodular regenerative hyperplasia
- Focal Nodular Hyperplasia
- Compensatory hypertrophy
- Post-necrotic regenerative nodules

Hepatocellular Adenoma

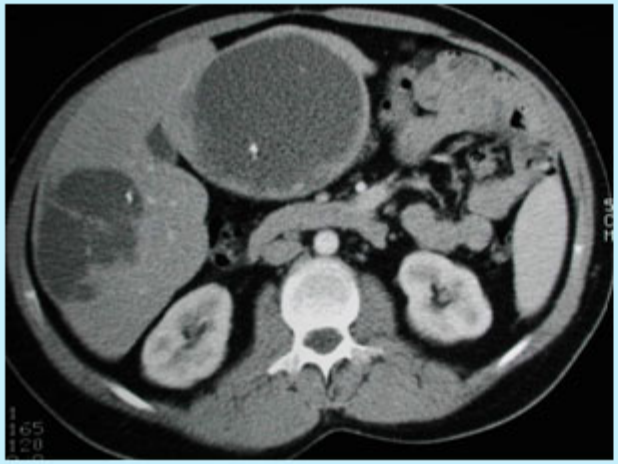

Multiple low attenuation adenomas are present in this patient with Von Gierkes disease. Note the coarse calcifications.

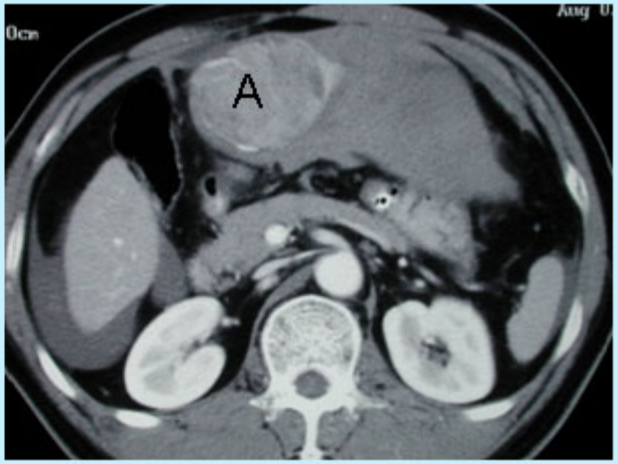

This CT scan shows rupture of an adenoma (A) with hemoperitoneum. Ruptured adenoma has a 20% mortality.

- Unlike adenomatosis (M=F), 90% of solitary adenomas occur in females.
- US findings are not specific, or masses may not be visible at all.
- On CT or MRI, may see 1 or more moderately enhancing masses.
- In patients with disorders that predispose to adenoma formation, such as the glycogen storage disease, a fatty liver may be identified with or without regenerative nodules.
- Patients with GSD are more likely to have multiple adenomas
- The first presentation may the recognized complication: bleeding!
- No bile ducts or portal triads are present.

Adenoma

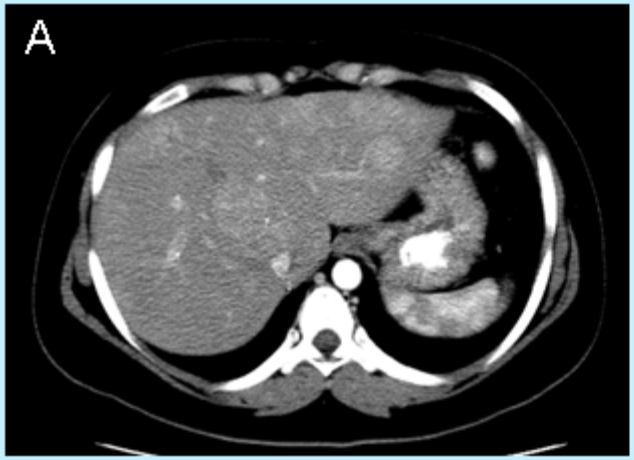

Multiple early-enhancing adenomas (A) are present in this otherwise healthy young female. On delayed phases, the lesions wash out briskly and appear as low attenuation masses throughout the liver (B).

- Despite imaging features overlapping with HCC, AFP is not elevated, patients tend to be younger, female, hepatitis serology negative and otherwise healthy.
- Biopsy is not recommended since it is unlikely to distinguish adenoma from a well-differentiated hepatoma.
- Surgeons like to remove solitary adenomas larger than 5cm. Smaller lesions, or when multiple are usually followed up with imaging & annual AFP levels.
- Adenomatosis is defined as >10 lesions, no steroid use, and elevated alkaline phosphatase.

Focal Nodular Hyperplasia

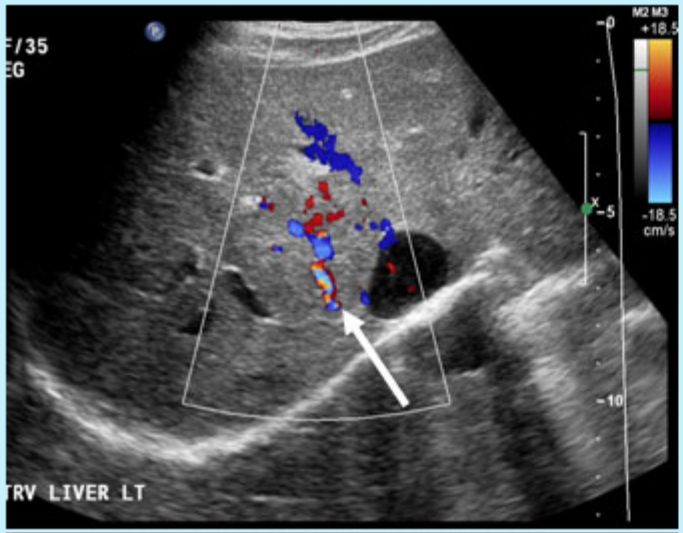

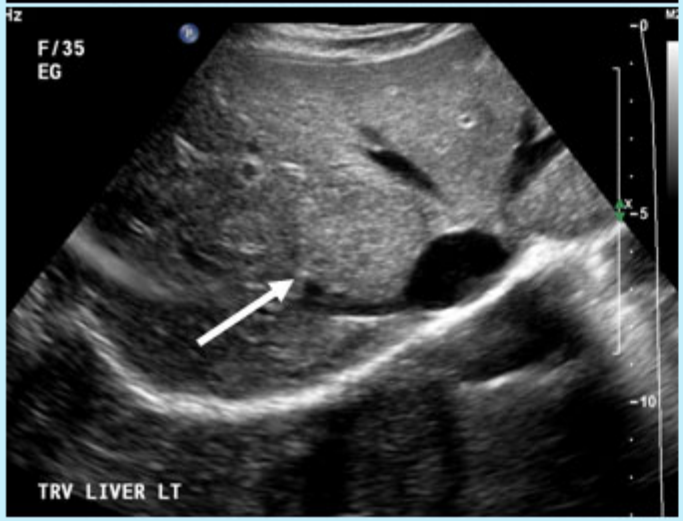

On ultrasound, color Doppler may show central vessels in what is typically a solid mass with no distinguishing imaging characteristics (arrow, top left). On gray scale, features are non-specific and may range from being isoechoic (arrow, bottom left) to hypoechoic (below)

Tumors of hepatocellular origin

Focal Nodular Hyperplasia

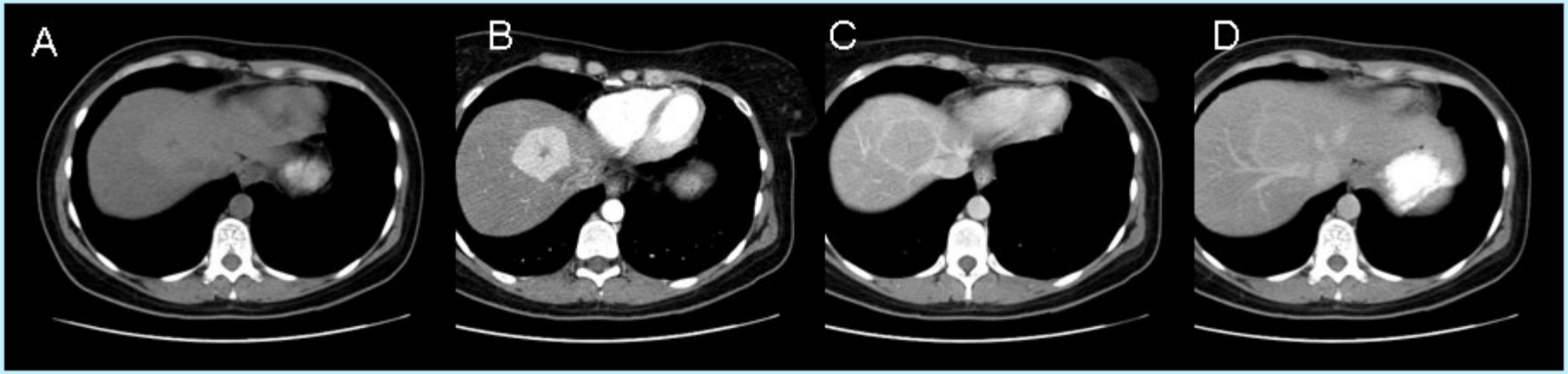

This sequence depicts the characteristic CT enhancement features of FNH. The tumor is typically slightly higher attenuation to surrounding normal parenchyma pre-contrast (A), with brisk homogeneous enhancement during the bolus phase (B) except for the central scar, and early washout with drainage into veins during the non-equilibrium phase (C). FNH may be barely visible on delayed phases when the central scar has filled in entirely (D). This brisk homogeneous enhancement pattern is also seen with contrast-enhanced dynamic MRI.

MRI of Focal Nodular Hyperplasia

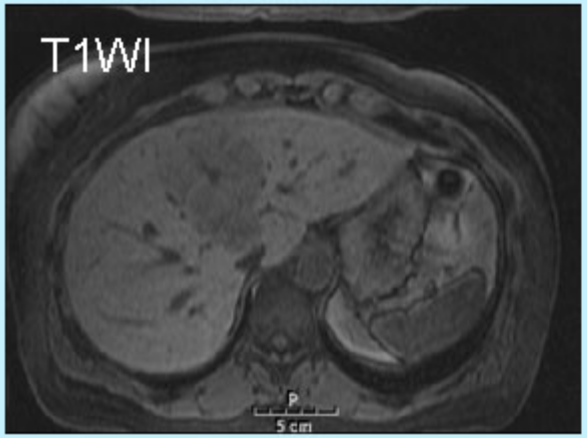

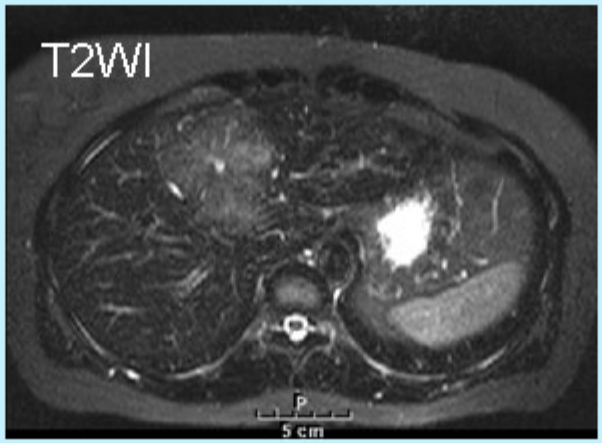

The characteristic MR features of FNH include low attenuation T1 (top left), high attenuation T2 (top right), brisk enhancement of mass but not central scar during the bolus phase (bottom left) and delayed filling in of the central scar (arrow, bottom right).

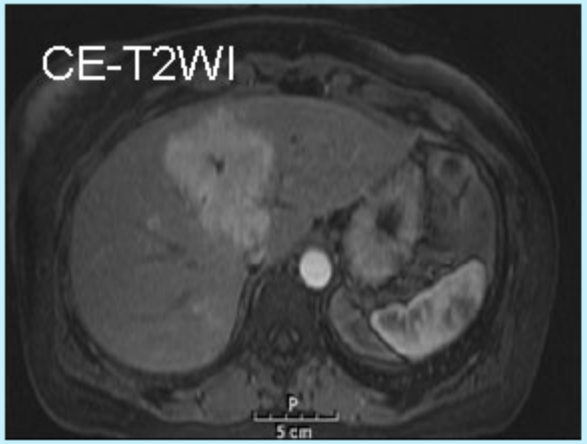

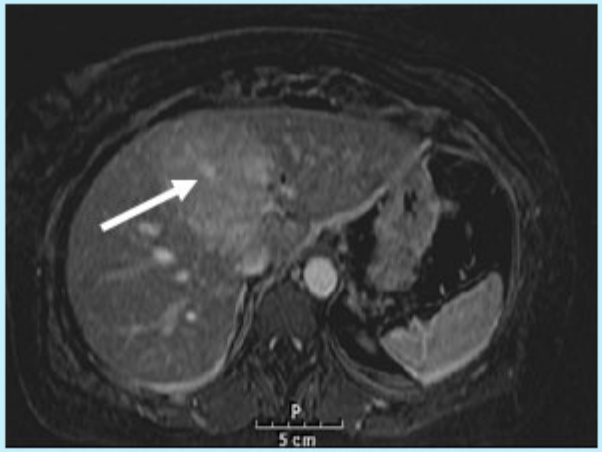

- Normal biochemistry.
- 20% have no central scar.
- Not caused by OCP
- No malignant transformation.
- Must recognize to avoid biopsy.

- Represents localized hepatocyte response to underlying congenital AVM.
- Contains all expected liver parenchymal elements, but in a disorganized mass.
- OCP use is associated with complications in FNH (hemorrhage, infarct, rupture).
- Proliferating bile ducts are present but they typically don't communicated with the biliary tree.
- No capsule is seen; unlike FNH, most adenomas are encapsulated.

FNH Variants: 20% of FNH are not “classic”. These include 3 subtypes; telangiectatic, FNH with cytologic atypia, and mixed hyperplastic and adenomatous FNH. The Nonclassic FNH always have bile duct proliferation and may thus be seen with contrast agents that are taken up by biliary epithelium.

Telangiectatic FNH

- No central scar is present on imaging studies
- No architectural distortion
- Hepatic plates separated by dilated sinusoids
- Represents 9-19% of cases of FNH
- Arteries have no intimal proliferation
- All have bile duct proliferation
- Abnormal vessels drain into sinusoids rather than larger veins
- Shares some imaging features with adenoma

P Attal et al. *Radiology* 2003; 228: 465-72

Distinguishing FNH from Adenoma

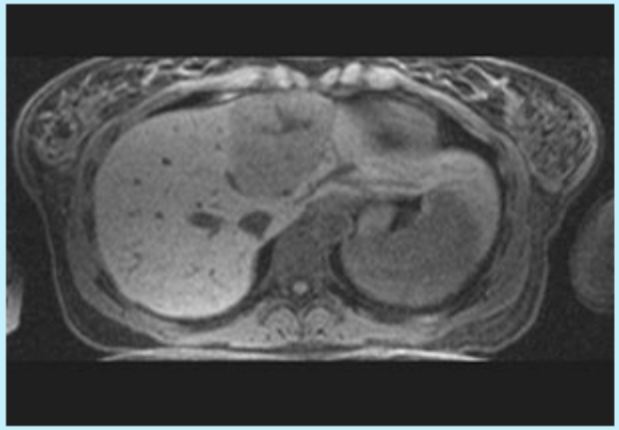

Pre-contrast

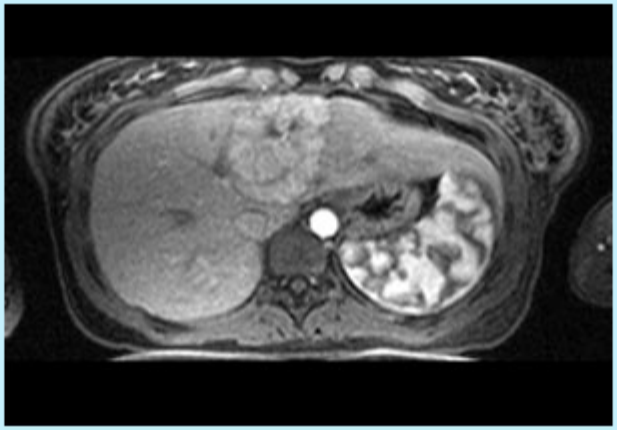

Post-contrast

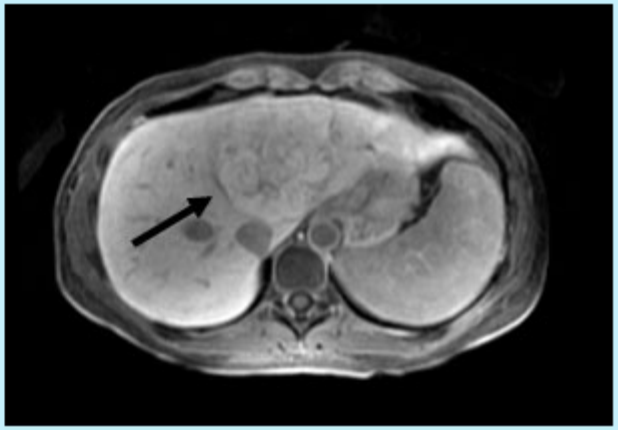

Delayed

Gadolinium-BOPTA, an agent that is taken up and excreted by biliary epithelium, is 97% specific for FNH. The MR images above show the brisk enhancement of the tumor after contrast administration. The delayed images, obtained 60 minutes after contrast was administered, show uptake of BOPTA by the tumor (arrow).

Cannot distinguish FNH & Adenoma pre-contrast or with DCE. Approximately 97% of FNH take up BOPTA, none in adenomas.

Grazioli et al. Radiology. 2005;236:166-77

Regenerative Nodules

- Non specific imaging features on both US and CT.
- May show brisk early enhancement on bolus phase CT scans.
- Remain slightly hyperattenuating on non-equilibrium phases.
- Small nodules may be a transient observation.
- Enhance if possess dysplastic features.
- Although usually bright on T1WI, the presence of iron or copper in siderotic nodules produces low signal on both T1 and T2-weighted MR images.
- Suggest the diagnosis in proper clinical context.
- May be indistinguishable from small HCC, especially since AFP may be elevated.

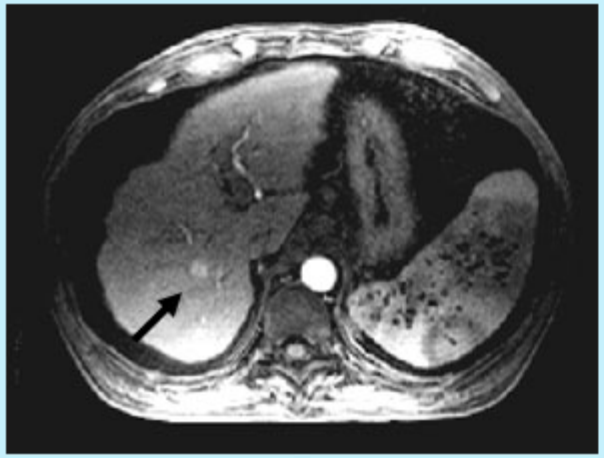

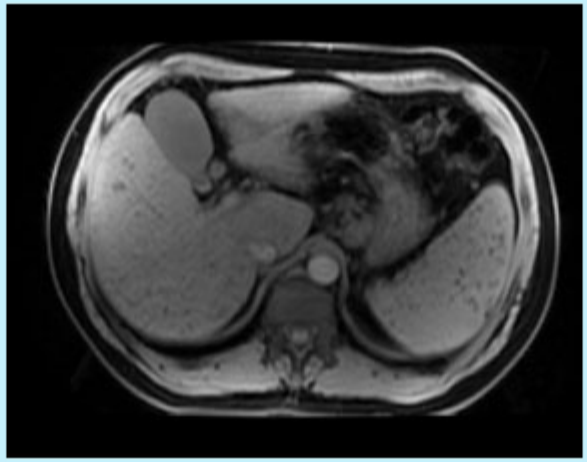

These images show low signal siderotic nodules in the liver and spleen (Gamna-Gandy splenic bodies). During the bolus phase, note the brisk enhancement of a small right lobe regenerative nodule (arrow, image left).

Regenerative Nodules

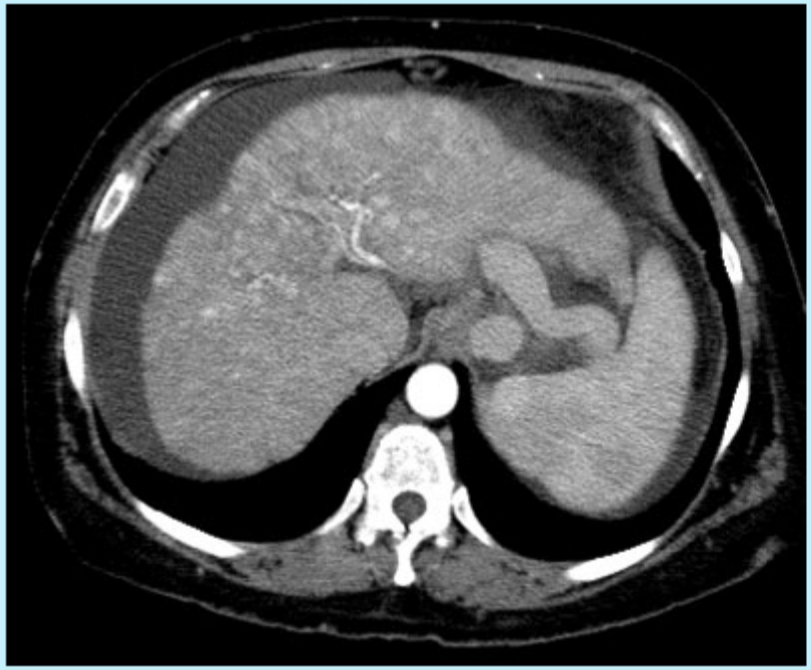

This contrast-enhanced CT scan image shows multiple small early enhancing lesions throughout the liver. These MRI-confirmed regenerative nodules are indistinguishable from multifocal HCC or vascular metastases. On follow-up, it is not unusual to document that some of these lesions seem to disappear.

Nodular Regenerative Hyperplasia

In this 32 yr old female with an autoimmune disorder, massive post-inflammatory regeneration of the liver produced large nodules, dark on T1 & T2 MR images due to iron deposition.

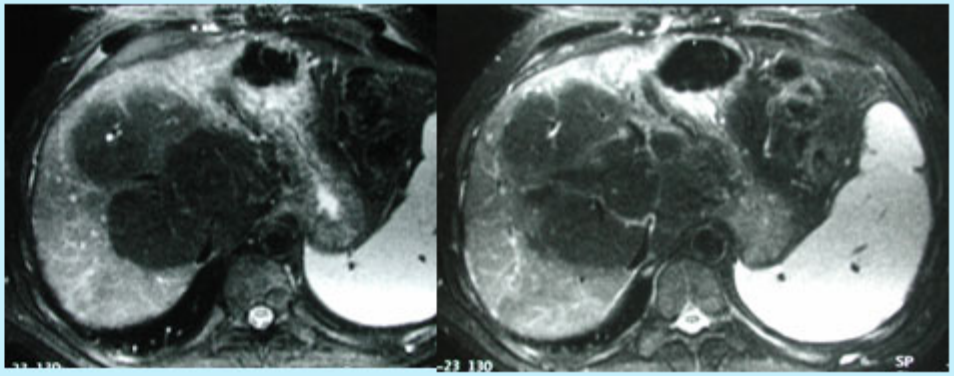

Large nodules resulting in Budd Chiari syndrome

Siderotic nodules from chronic congestive failure, causing the so-called **nutmeg liver**.

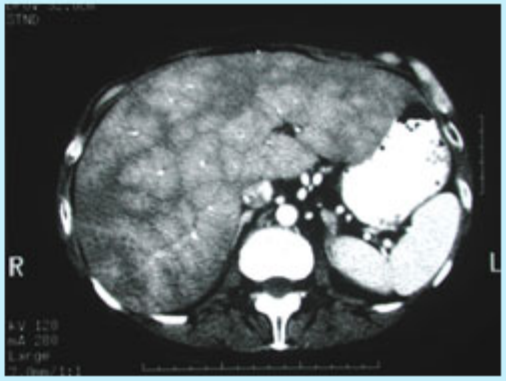

Tyrosinosis

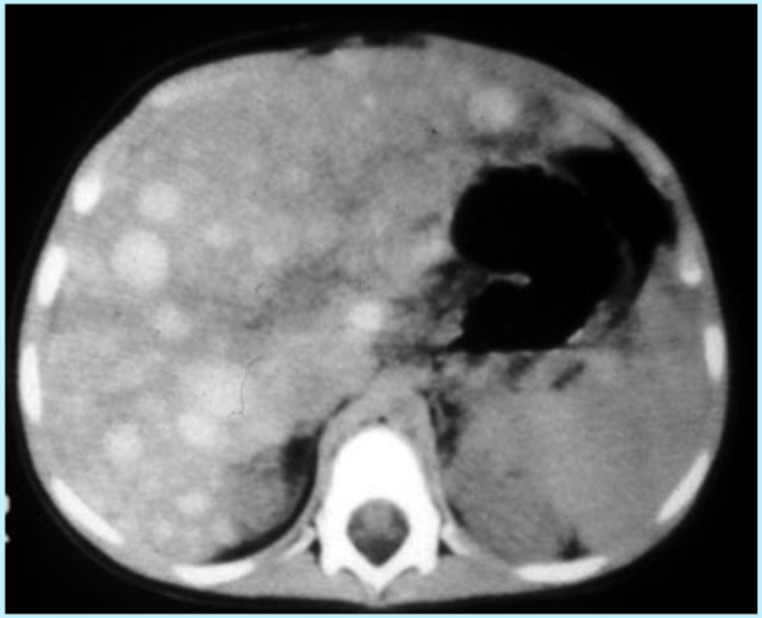

This non-contrast-enhanced CT scan image shows multiple high attenuation masses distributed throughout the liver of this young 3 year old child with hereditary tyrosinemia. These masses represent siderotic nodules.

Image courtesy of Jonathan Goldin, MD

Von Gierke Disease

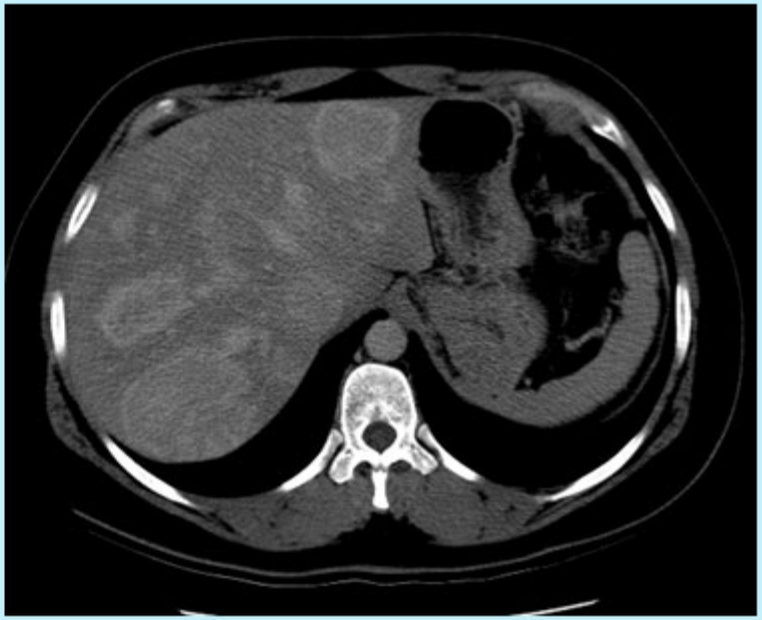

This non-contrast-enhanced CT scan of the liver shows the diffuse low attenuation background due to fatty replacement. The adenomas are seen as multiple higher attenuation masses in the liver on this unenhanced image.

Tumors of Cholangiocellular Origin

- Bile duct cysts
  - *Intrahepatic choledochal cysts*
- Peribiliary gland hamartomas
- Peribiliary cysts
- Biliary Cystadenomas
- Hepatic foregut cysts
- Biliary papillomatosis

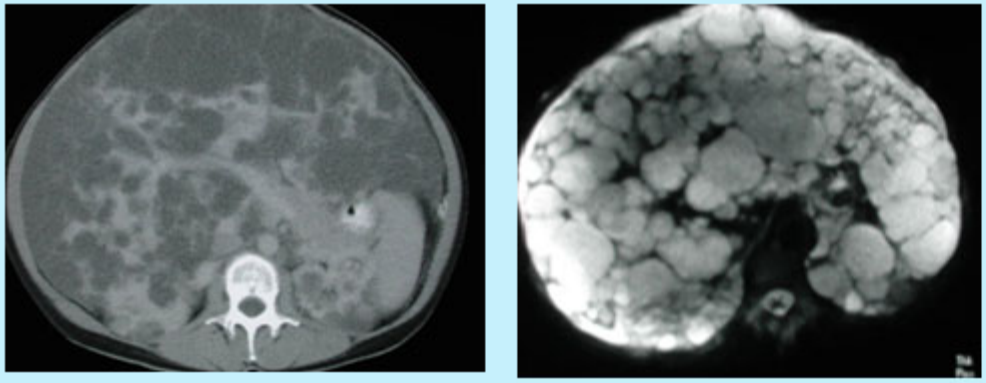

Polycystic liver disease: this CT (left) and T2W-MRI image show diffuse replacement of liver by innumerable simple cysts.

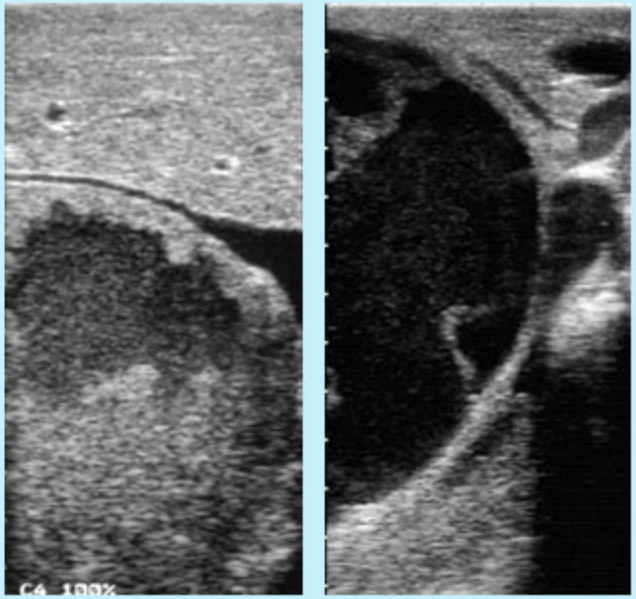

The simple hepatic cyst is lined by biliary epithelium and may be single or multiple. Complications such as hemorrhage or infection result in additional imaging features such as debris, septations and complex internal fluid characteristics.

Bile Duct Hamartoma's

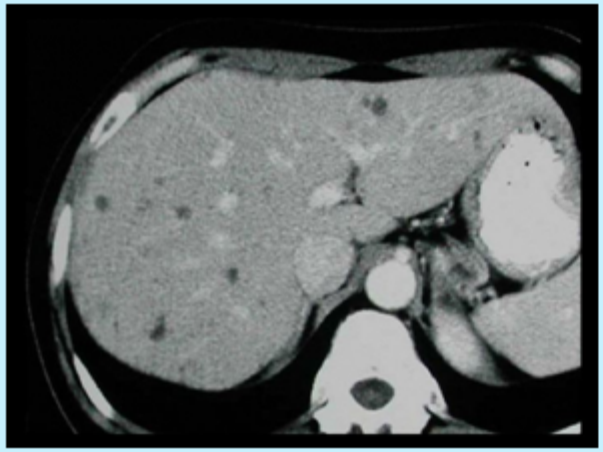

Multiple widely scattered small low attenuation lesions detected incidentally in an otherwise healthy patient are characteristic of bile duct hamartoma's, also known as von Meyenberg complexes. These cysts are usually too small to be seen with ultrasound.

Caroli disease

Note the somewhat complex cystic "mass" abutting the left portal vein in this patient with isolated segmental Caroli disease.

Bile lake: this cystic bile lake (*) developed following left hepatic artery occlusion.

Peribiliary Cysts

Also known as hepatic hilar cysts or mucinous hamartomas of the bile ducts.

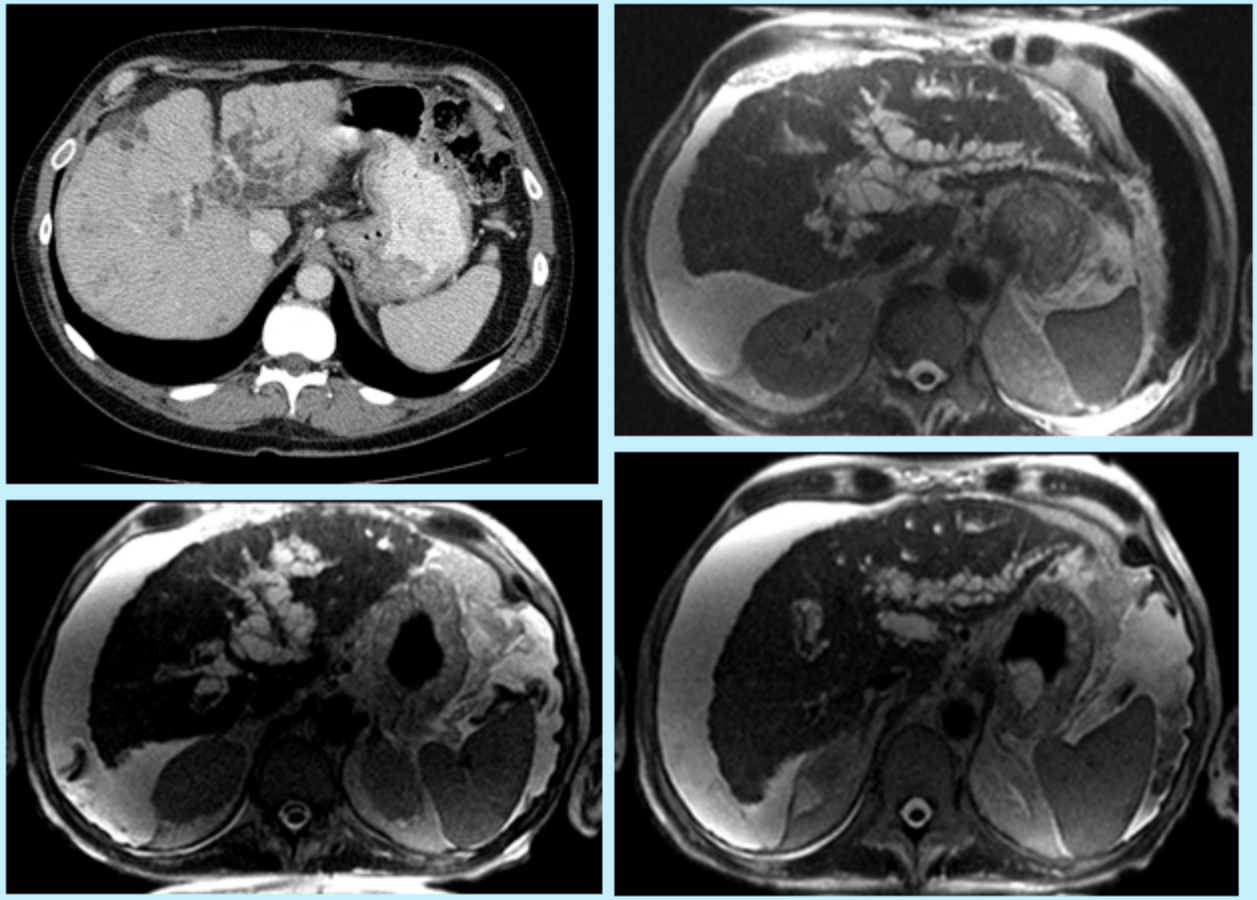

Typically seen adjacent to large intra- & extrahepatic ducts in asymptomatic patients. Cysts can actually cause narrowing of the ducts leading to obstruction. Can be as large as 2cm.

Peribiliary cysts, cystic dilatation of glands in the bile duct walls, are seen in severe liver disease of varying etiologies. On ultrasound, these cysts may give the false impression of dilated intrahepatic ducts.

Baron R et al. AJR 1994; 162: 631-6

Intrahepatic choledochal cyst

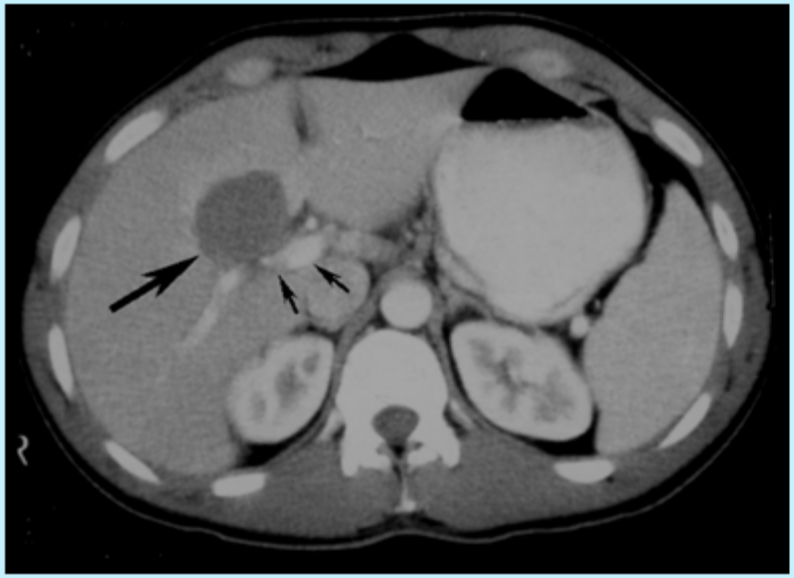

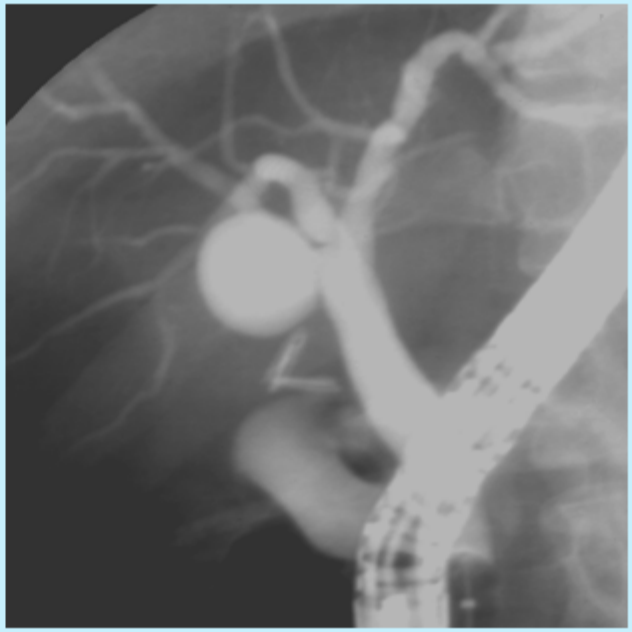

Choledochal cysts may arise from the intrahepatic ducts and manifest as cystic liver lesions. In this example, a solitary choledochal cyst (on ERCP, top right) presents initially as a cystic mass nexto the portal vein (top left). Intraoperative ultrasound (bottom left) shows the cyst communicating with the common hepatic duct.

Biliary Cystadenoma

This contrast-enhanced CT scan shows a complex enhancing solid and cystic mass with several coarse calcifications. Enhancement of the nodular components is a feature of cystadenomas and cannot be used to distinguish these from cystadenocarcinomas. Another similar but more aggressive tumor which typically arises along the right lateral hepatic margin is the epithelioid hemangioendothelioma.

This contrast-enhanced CT scan shows one unusual feature of more advanced biliary cystadenoma's: extension and growth of the tumor into an adjacent bile duct (arrow)

Hepatic cysts pitfalls:

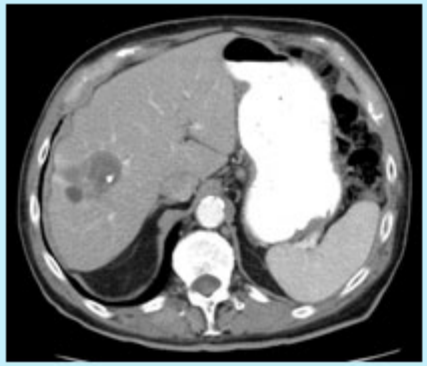

Hemangioma

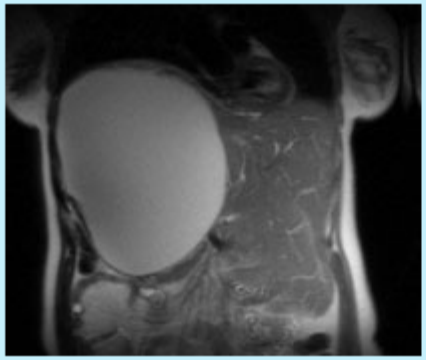

Cystadenoma

Echinococcus granulosis

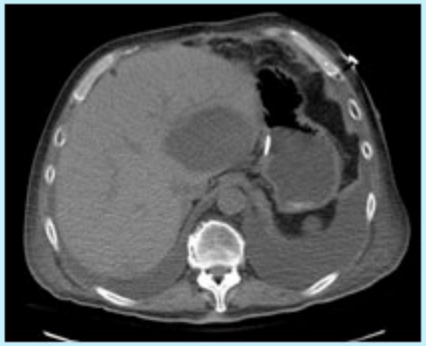

Infarction

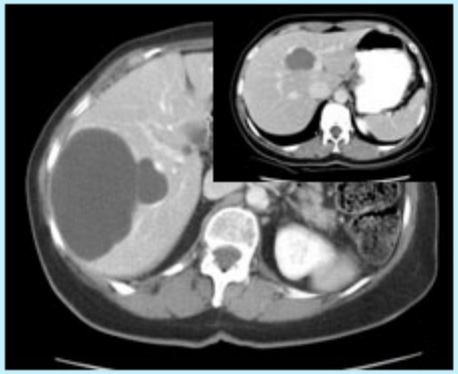

Biliary cystadenoma

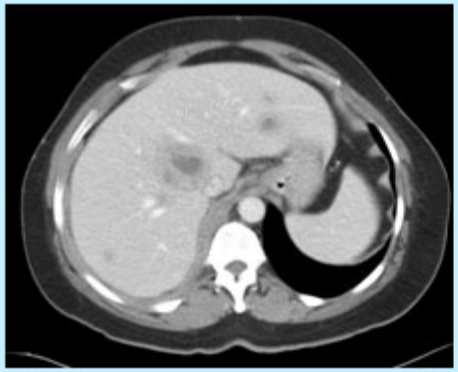

Abscesses

Central scar of FNH

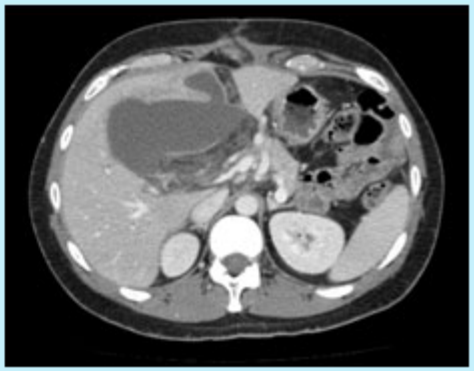

Pseudocyst of pancreas

The above-depicted cystic liver lesions may all falsely simulate benign simple cysts.

Tumors of Mesenchymal origin

- **Cavernous hemangioma**
- **Peliosis hepatis**
- **Pericytoma**
- **Focal fat**, pseudolipoma
- **Inflammatory pseudotumor**
- **Hepatoblastoma**
- Myelolipoma
- Hamartoma
- Infantile hemangioendothelioma
- Heriditary hemorrhagic telangiectasia
- Lymphangioma
- Leiomyoma
- Solitary fibrous tumor
- Langerhans cell histiocytosis
- Rarities: xanthomatous neuropathy, chondroma, myxoma, mesothelioma

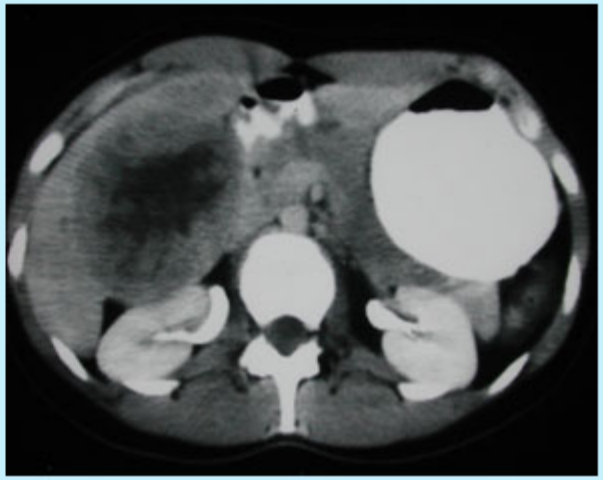

Hepatoblastoma

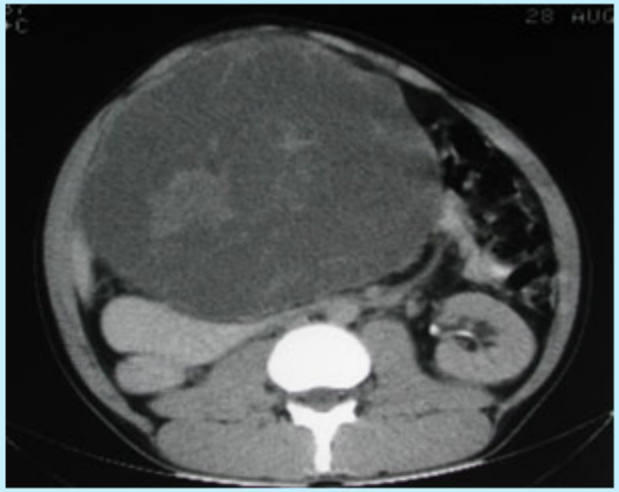

Pericytoma

One clue to the presence of a pericytoma is their association with hypoglycemia

Hemangioma

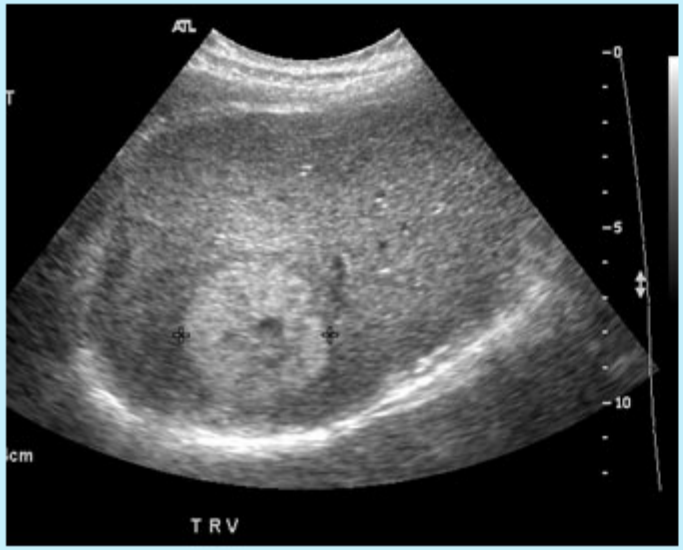

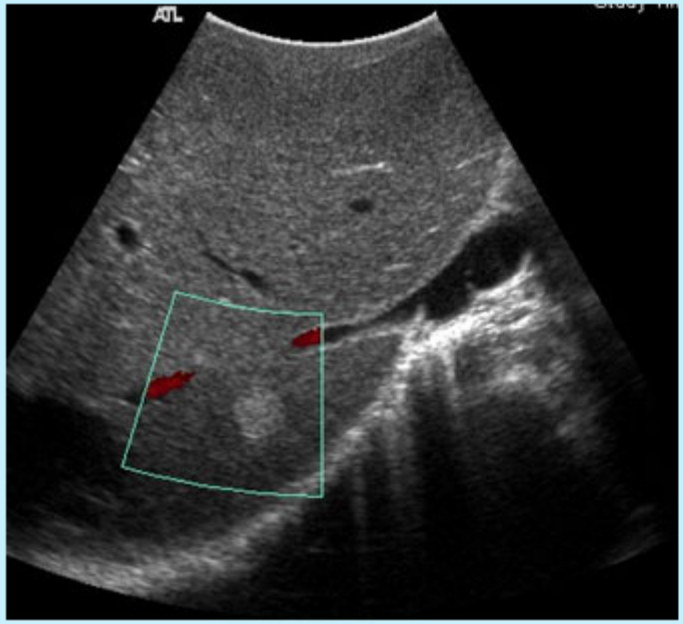

Cavernous hemangioma

Hemangioma's have characteristic imaging features on US, CT & MRI. Note the etched margin surrounding the uniformly echogenic mass in the liver (top left), and lack of Doppler flow (bottom left). Giant cavernous hemangioma's of the liver (above) (defined as being >5cm in diameter) typically have an atypical sonographic appearance and often require confirmatory imaging with MRI. This lesion above does not have an etched margin and is not uniformly echogenic.

CT and MRI of hemangioma

The CT and MRI features of hemangioma's are similar. Both show progressive centripetal puddling of contrast depending on the extent of fibrosis.

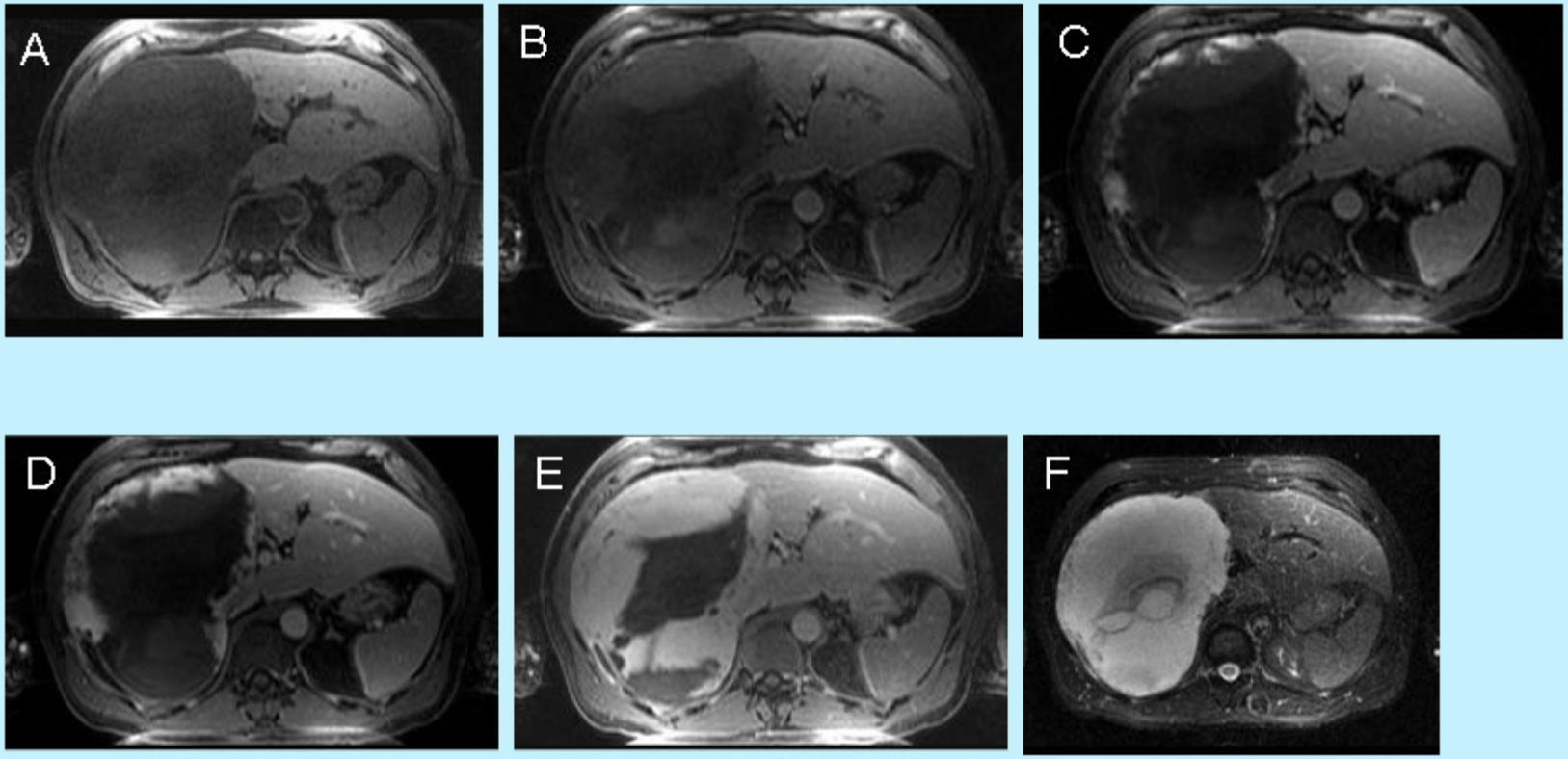

Hemangioma's are typically bright on T2WI. These images also show the progressive centripetal filling in of the hemangioma.

Focal fat - mass-like appearance

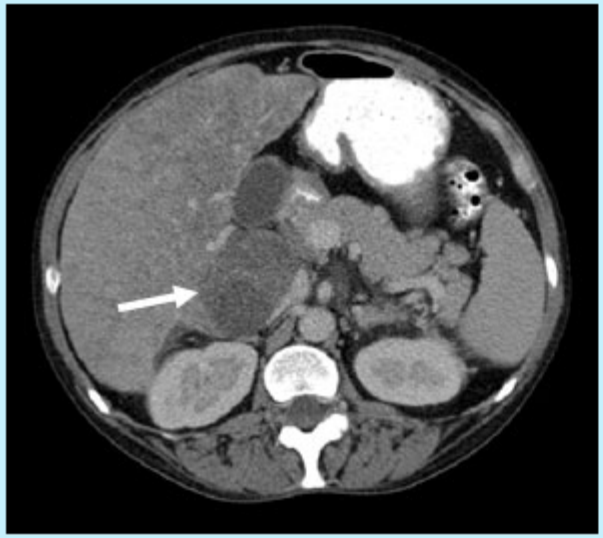

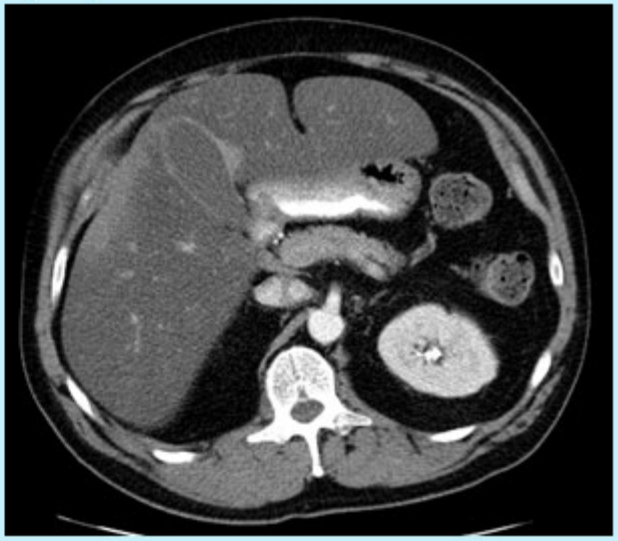

Different manifestations of fatty replacement in the liver. Margins are "geographic", no mass effect is usually evident, and vessels may traverse the fat. Given the atypical appearance of these low attenuation masses, MRI is often suggested for characterization and to exclude fat-containing masses.

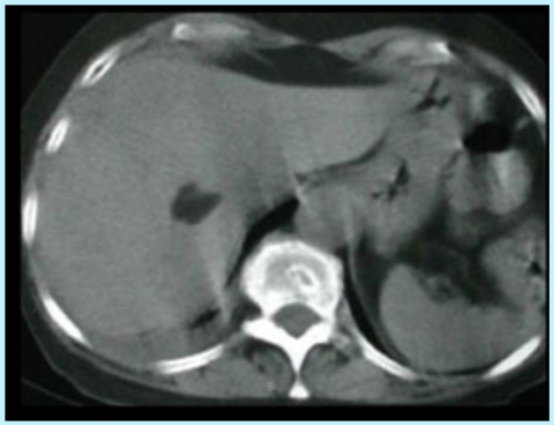

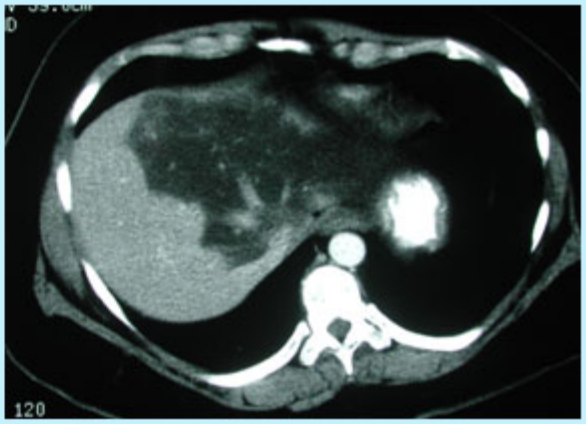

Hepatic Angiomyolipoma

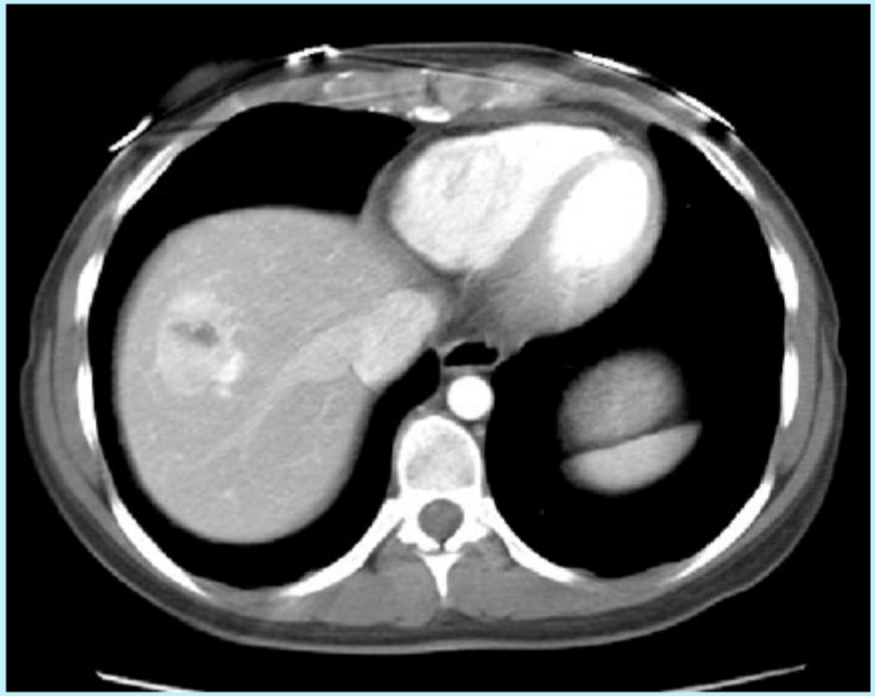

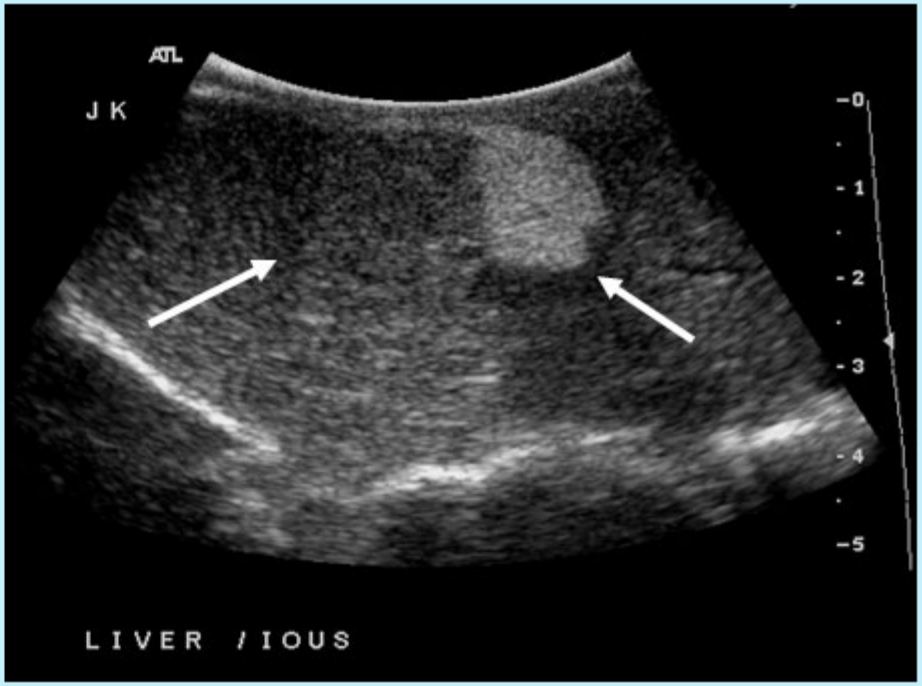

On both CT and ultrasound, the lesion may be mistaken for an hemangioma due to its brisk contrast-enhancement on CT and solid echogenic appearance on ultrasound. Below, the characteristic features on MR are shown.

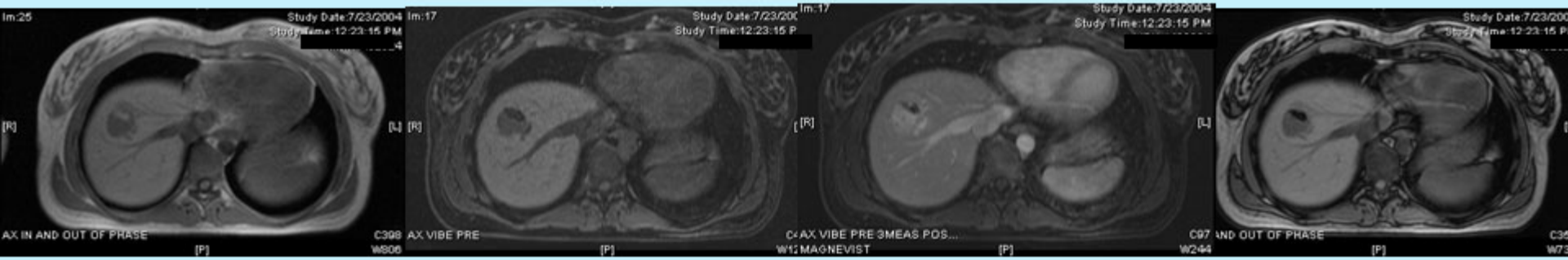

Peliosis Hepatis

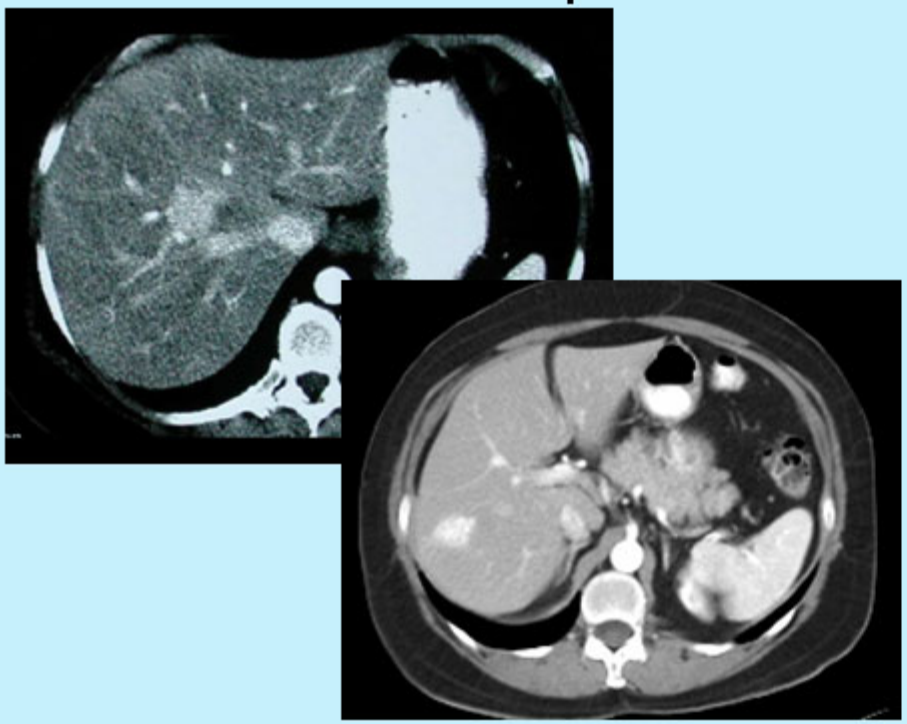

Peliosis hepatis is characterized by multiple endothelial-lined blood filled spaces which communicate with adjacent sinusoids. It may appear as focal areas of brisk contrast enhancement. The appearance may be similar to FNH and hemangioma's.

Paraganglioma

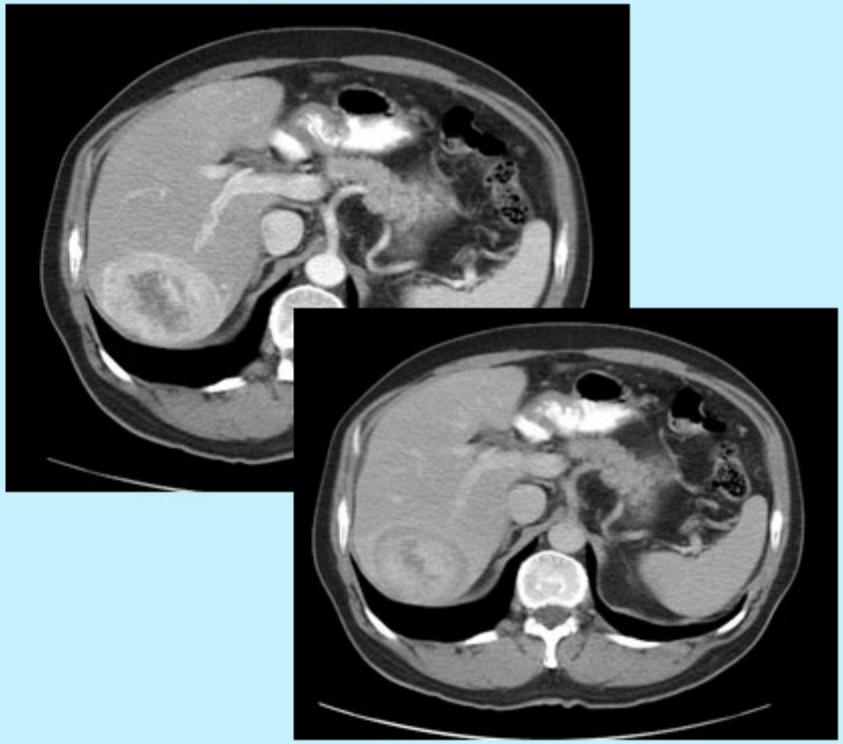

Paraganglioma's of the liver, like many of the mesenchymal tumors, have no unique imaging characteristics other than being solid, single or multiple, and have varying degrees of contrast enhancement. Diagnostic biopsy is usually required.

- **Tumors of Mixed Cellular Origin**
  - Teratoma
  - Mesenchymal Hamartoma

Rare tumors, no distinguishing imaging features, require resection since biopsy may not be definitive.

- **Miscellaneous tumors**
  - Adrenal rests, intrahepatic ectopia's
  - Plexiform neurofibroma's
  - Ossifying stromal epithelial tumor
  - Hepatic pregnancy
  - Glomus tumors
  - Extramedullary hematopoeisis

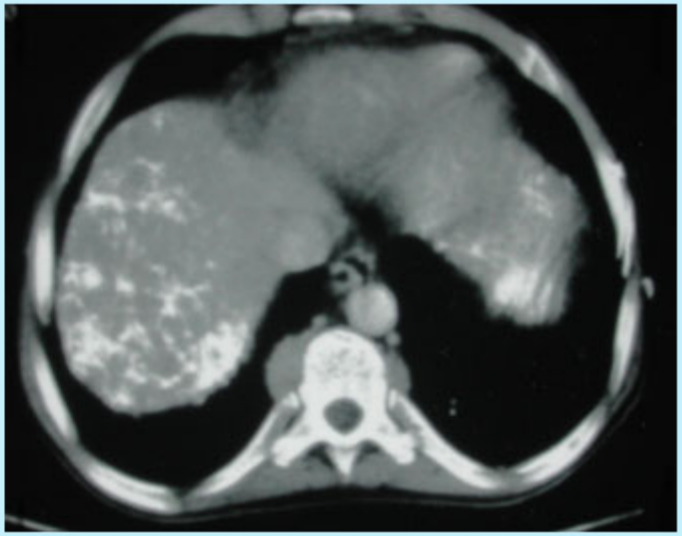

Extramedullary Hematopoeisis in Thallassemia: EMH may be focal or diffuse, and usually contains fatty components. In this case, dystrophic calcification has occurred in the widely-distributed lesions.

Pseudotumors of the liver: In this category, infections, post-treatment change, trauma vascular anomalies and mass-like perfusion changes.

- **Infections**
  - Septic emboli: diverticulitis
  - Inflammatory disorders of the liver:
    - Sarcoidosis
    - Inflammatory pseudotumors
  - Partially or previously treated abscesses
  - Infections that can simulate tumors
    - Echinococcus granulosis
    - Fasciola hepaticus

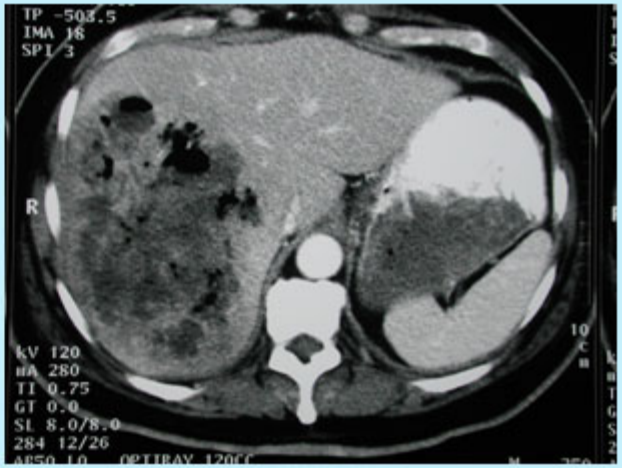

Liver abscesses

Hepatic abscess

The complex solid and cystic multiseptated appearance of hepatic abscesses may simulate cystadenomas. Clinical features usually support the diagnosis of abscess.

Treated abscess

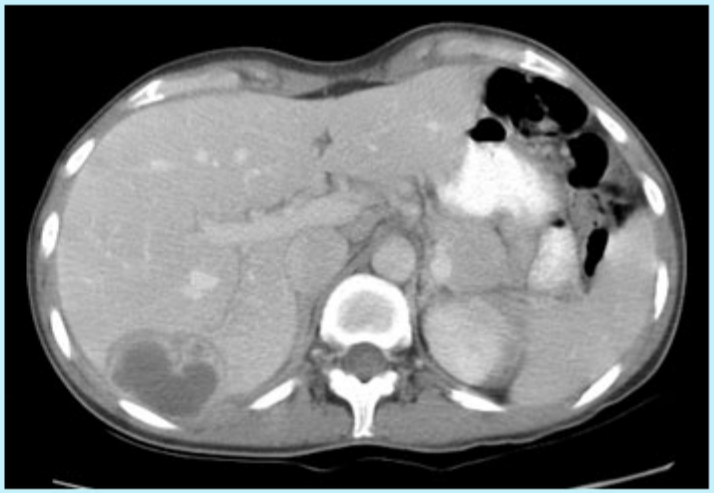

Complete or incomplete treatment of abscesses may result in changes that simulate a simple cyst.

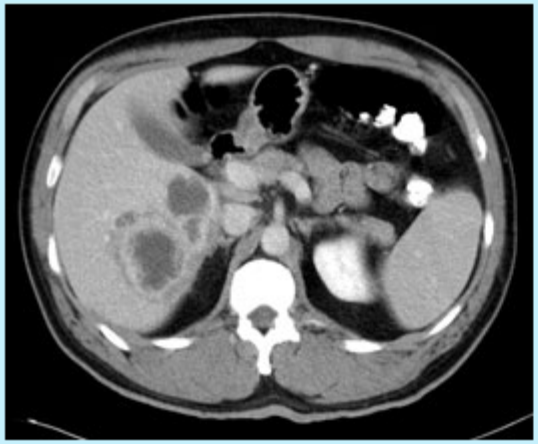

Treated lymphoma

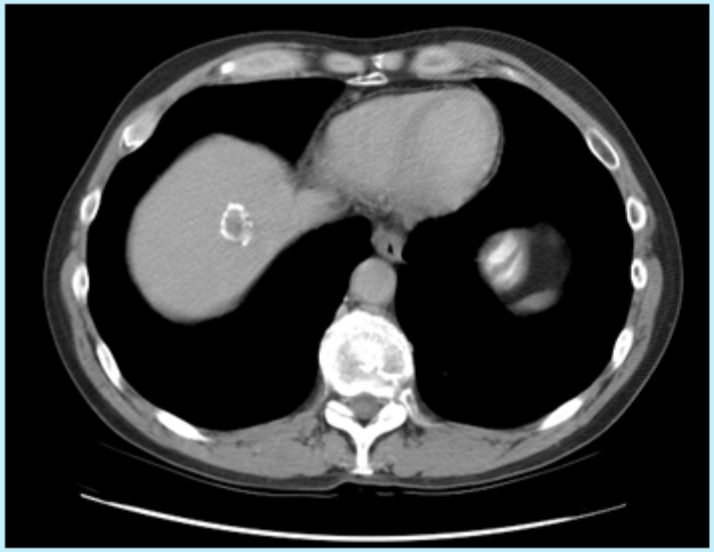

Following successful treatment of this hepatic lymphoma, this ring-like area of calcification was all that remained in the liver.

Inflammatory Pseudotumor

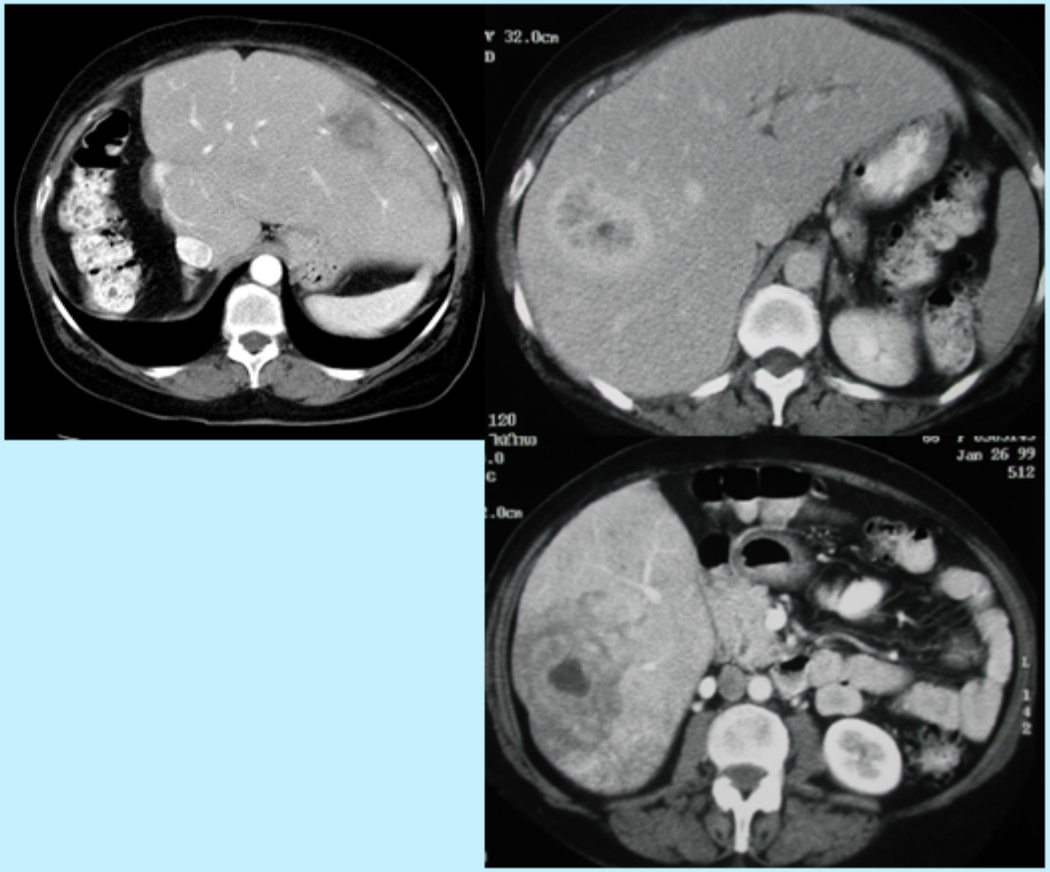

Inflammatory pseudotumors have a spectrum of appearances, but most commonly appear as solitary or multiple solid masses with enhancing components. Biopsy is required for diagnosis.

Echinococcus Granulosis

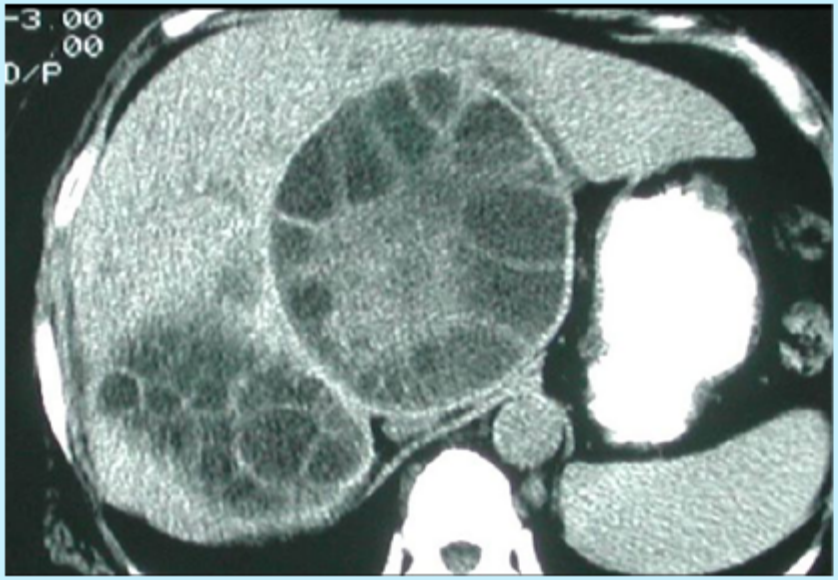

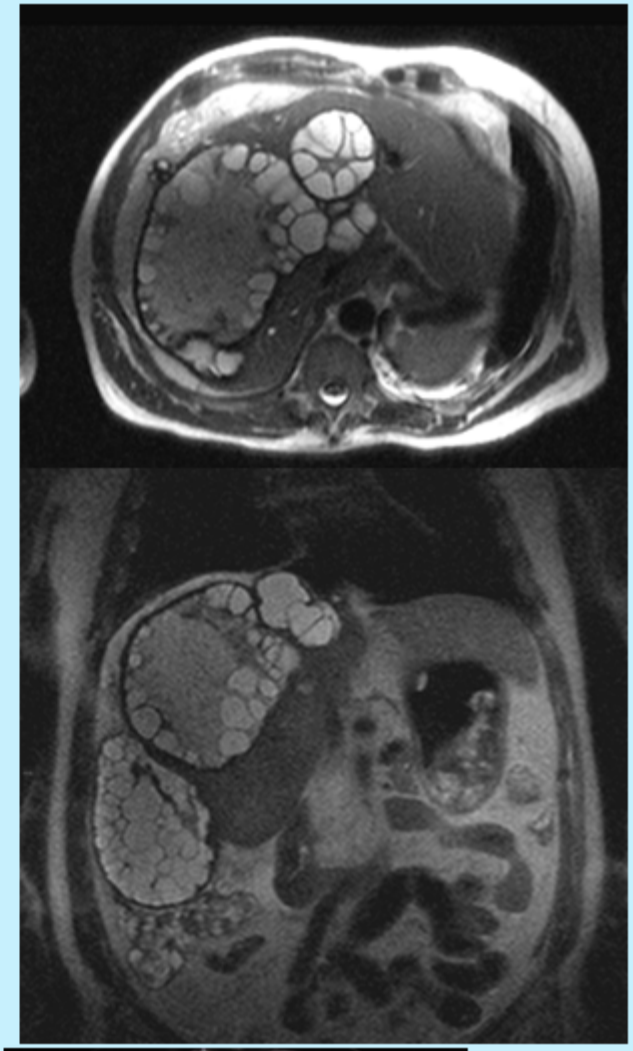

These are characteristic CT and MRI appearances of echinococcus granulosis, with cystic well-circumscribed masses containing multiple peripheral daughter cysts, with or without peripheral coarse rim calcification.

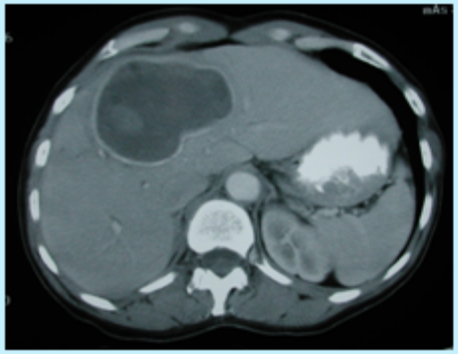

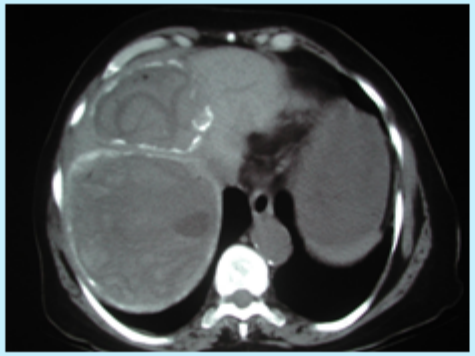

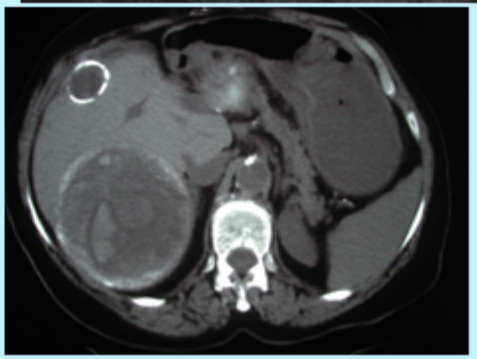

Fasciola hepaticus

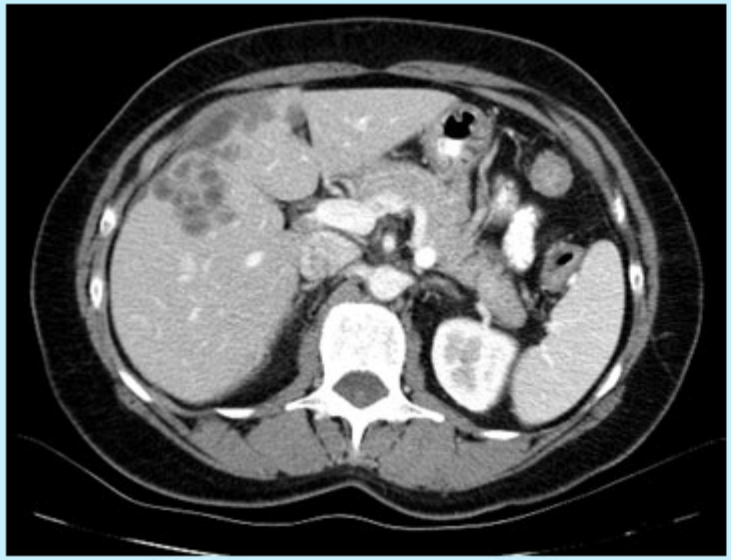

The parasite Fasciola hepaticus invades the liver capsule to burrow through the parenchyma seeking out bile ducts. This CT scan shows a complex cystic mass in the periphery of the right lobe of the liver due to conglomerate abscesses. Intraductal filling defects may be seen on ERCP or MRCP.

Entomoeba hystolytica

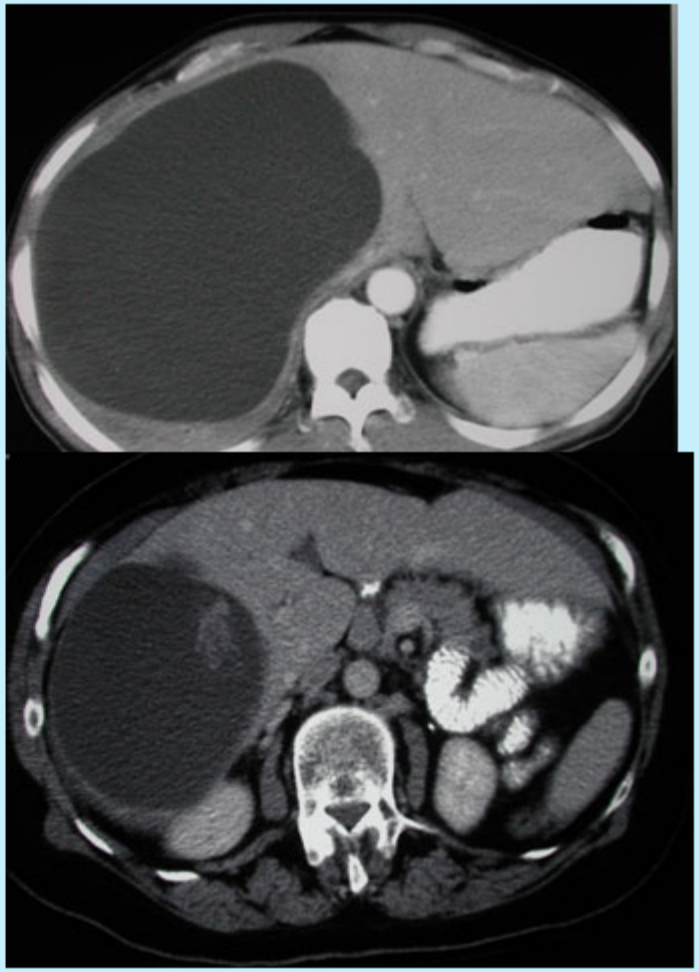

Amebic abscesses often contain copious amounts of debris. A more cystic appearance is seen once treatment commences.

Tuberculosis

These 2 cases of hepatic TB appear as multifocal low attenuation lesions throughout the liver. The diagnosis can be suggested by coexistent pulmonary, retroperitoneal or mesenteric findings.

Cryptococcus

Fungal involvement of the liver may be very subtle (left image) or easily visible when microabscesses are surrounded by hyperattenuating rims (image right).

Hepatosplenic sarcoidosis

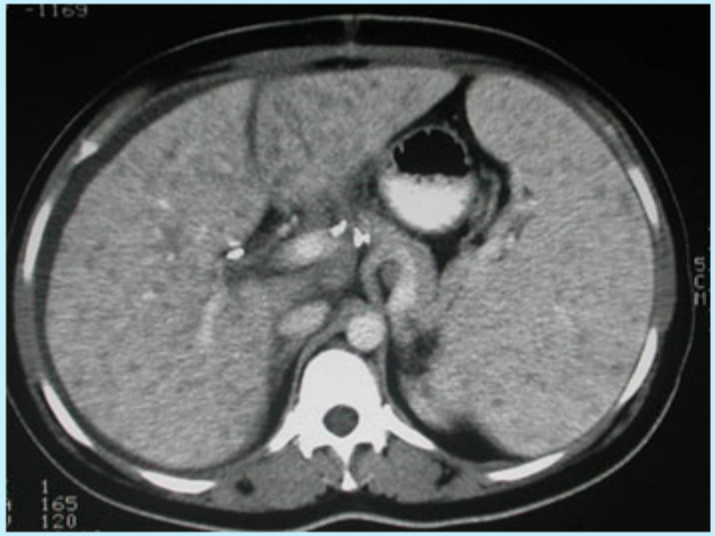

When visible in the liver, sarcoidosis may manifest as multiple variable-sized low attenuation lesions, often associated with multiple splenic lesions and lymphadenopathy. Rarely, sarcoidosis presents as areas of fatty replacement running parallel to the hepatic veins.

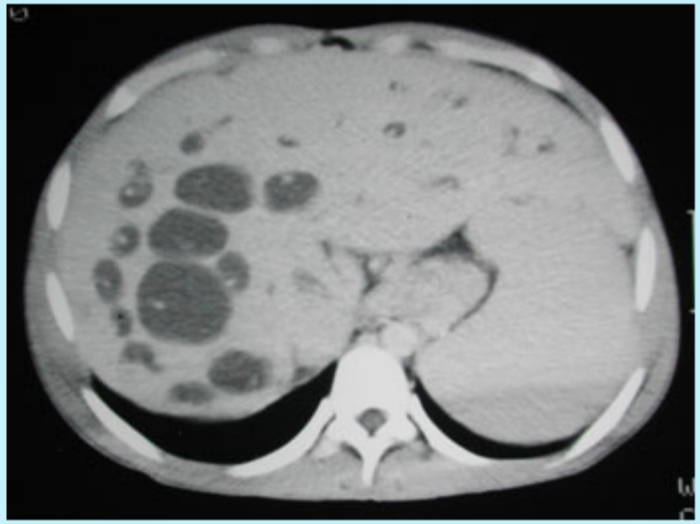

In the presence of multiple low attenuation lesions scattered throughout the liver, alternate considerations should include cystic metastases, polycystic liver disease, and as in this classic example, Caroli disease with the enhancing portal veins invaginating into the dilated bile ducts.

Post intra-arterial chemoembolization

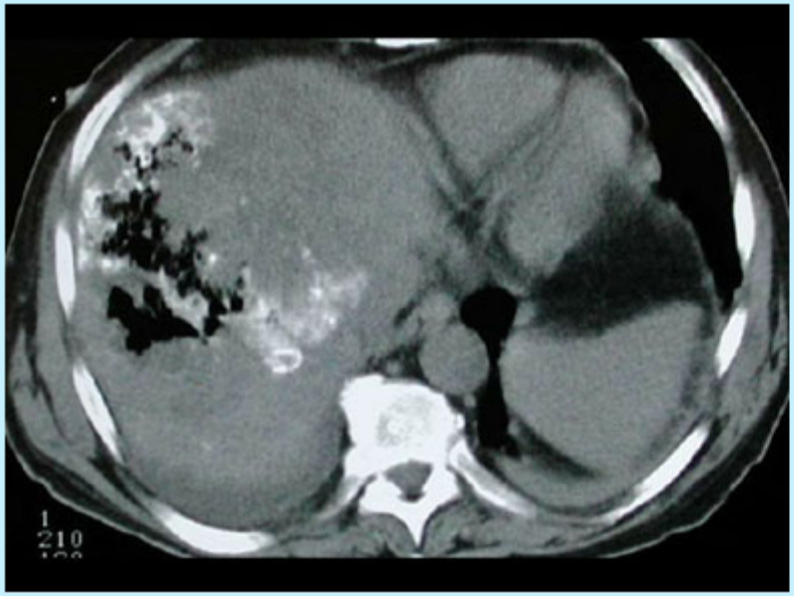

Following intra-arterial chemoembolization, this image shows gas in the tumor due to release of nitrogen as the tumor undergoes necrosis. The absence of a fluid should makes an abscess a less likely possibility. With abscesses and following chemoembolization, patients have RUQ pain and an elevated WBC count.

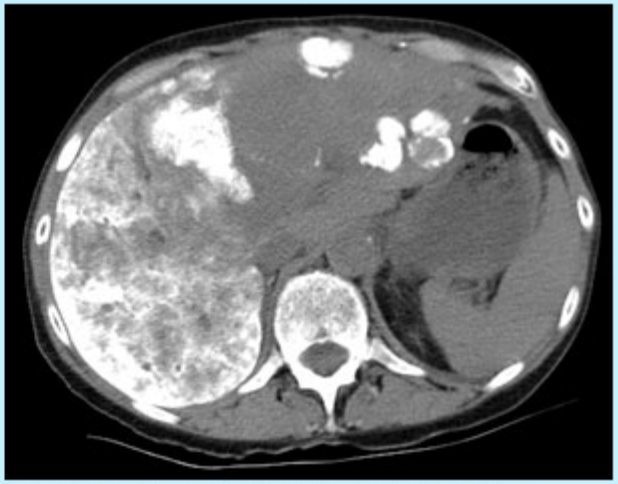

Immediately after chemo-embolization, high attenuation material is widely distributed throughout the liver.

Small aggregates of Lipiodol emulsion (arrows) may simulate the stippled calcification seen in mucinous hepatic metastases.

Post surgical defects of the liver

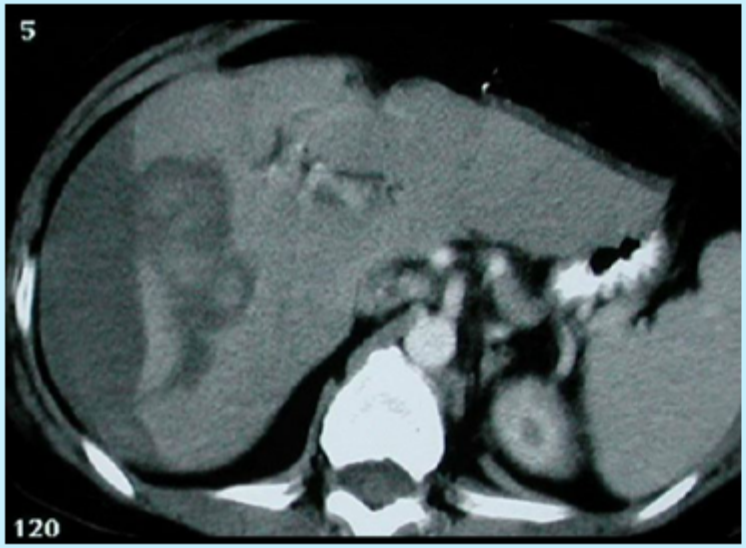

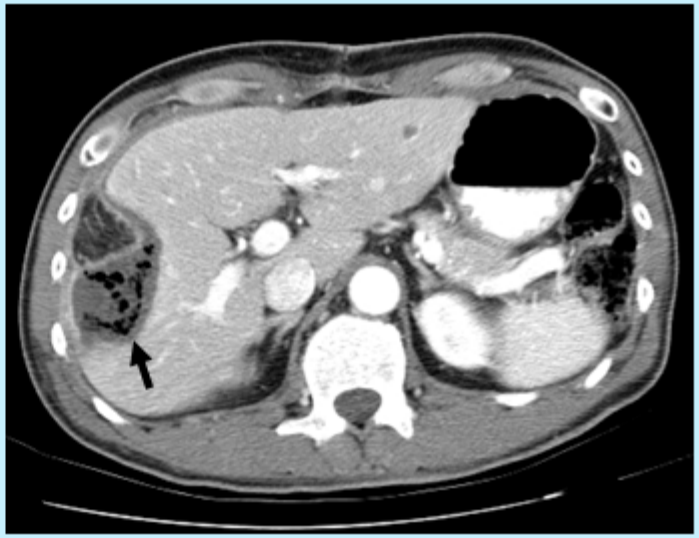

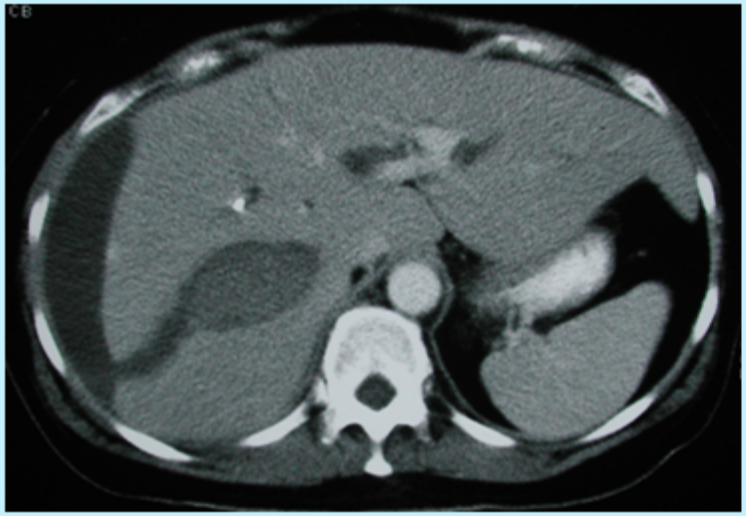

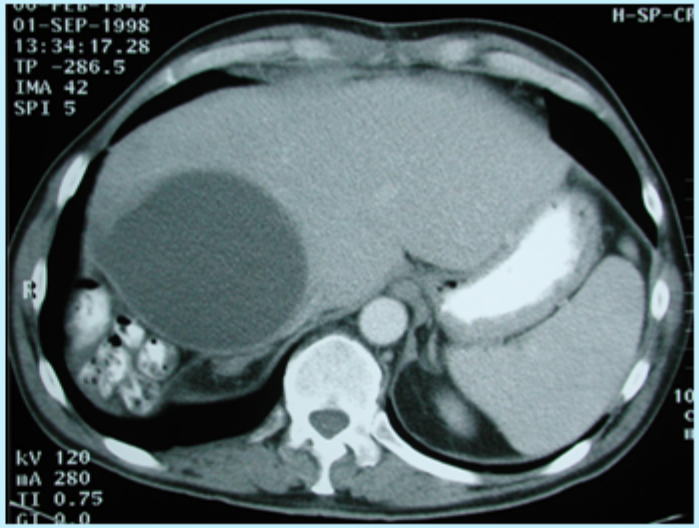

Post wedge resections: these are all expected post-operative defects in the periphery of the right lobe of the liver following wedge resections of colorectal metastases. The gas (arrow; top right image) is trapped within Surgicell, a hemostatic packing material.

Post-procedural pseudotumors that simulate benign liver tumors

- RF, microwave, ethanol & other percutaneous ablation therapies
- Omental packing, intrahepatic pancreatic pseudocysts
- Hematomas, traumatic lacerations and retractor injuries
- Bilomas: post trauma or transplant

Radiofrequency Ablation: post ablation focal non-enhancing masses are seen in the liver during this non-equilibrium phase acquisition; no enhancement should be seen in the zone of tumor ablation.

Retractor Injury: the focal low attenuation lesions in the left lateral segment of the liver (arrows) resulted from retractor compression during wedge resection of the right lobe lesion.

Post Radiation – multiphase CT appearance. The endothelial proliferation caused by XRT produces delayed enhancement of the exposed parenchyma following early diminished enhancement.

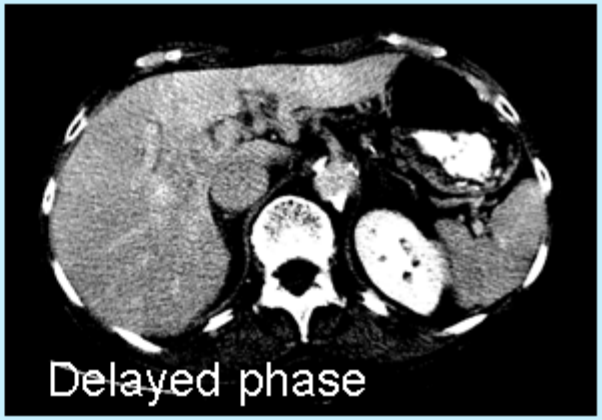

Post procedural complications may present as solid hepatic masses. These examples include a hematoma following biopsy of a mass (bottom left), bleed following RF ablation (middle), and post resection parenchymal bleed (bottom right).

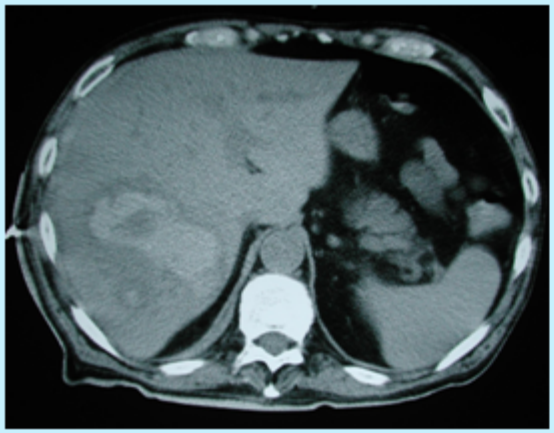

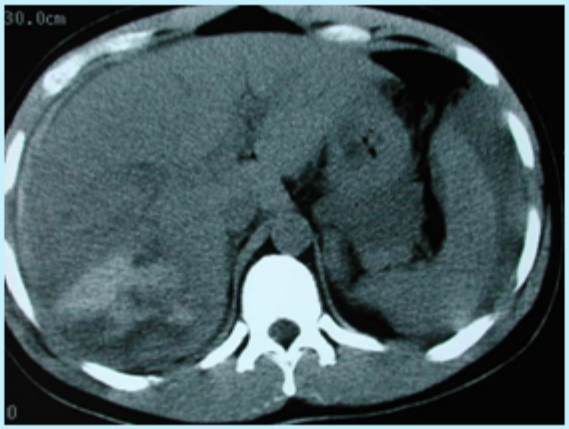

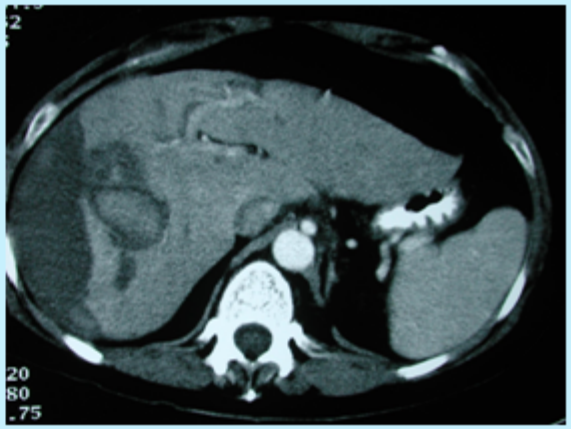

Vascular Pseudotumors

- Vascular malformations:
  - AVMs, Osler Webber Rendu, Hereditory hemorrhagic telangiectasia
- Infarcts: Hepatic artery occlusion, dissection or stenosis
- Transient hepatic attenuation differences & other shunts

Osler Webber Rendu syndrome: this contrast-enhanced CT scan shows innumerable early enhancing lesions throughout the liver, all confirmed on MRI to be consistent with hemangioma's.

Hepatic infarct from arterial occlusion: this contrast-enhanced CT scan shows a rounded low attenuation "lesion" due to downstream occlusion of a segmental hepatic artery.

Transient Hepatic Attenuation Differences: THAD's

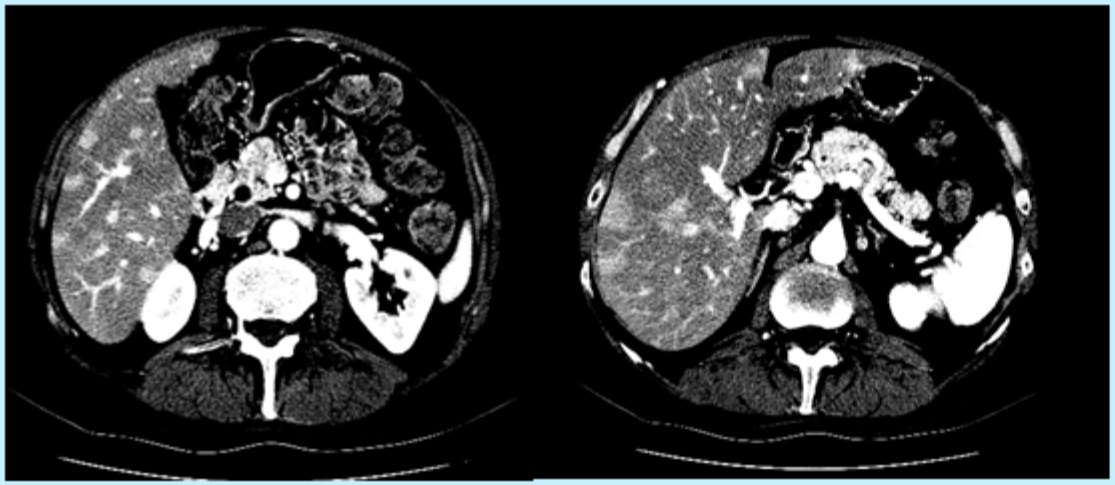

Multiple **Transient Hepatic Attenuations Differences** appear as peripheral wedge-shaped areas of vascular enhancement and are not seen during the portal phase.

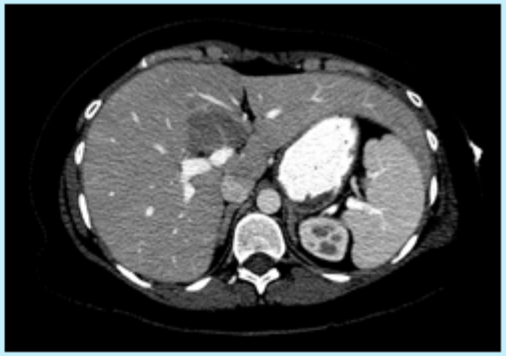

This focal area of reduced perfusion is thought to be due to cholecystic venous drainage from the gallbladder into the liver.

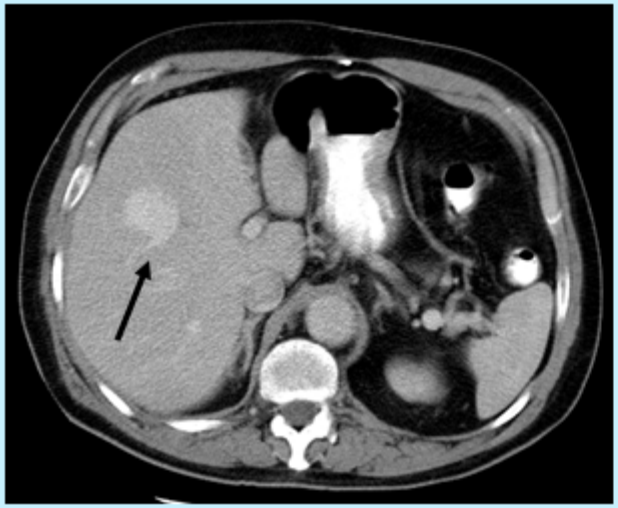

This spontaneous **arterio-portal shunt** appears as a rounded enhancing mass in the liver (arrow), and should be distinguished from a vascular solid tumor.

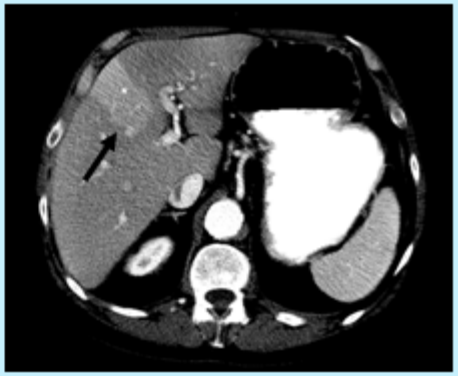

This focal area of enhanced arterial perfusion (↗) occurred secondary to a solid tumor.

Exophytic masses: several benign masses arise exophytically from the liver. Hemangioma's, regenerative nodules and adenoma's may be exophytic.

Endometriosis involving the liver capsule

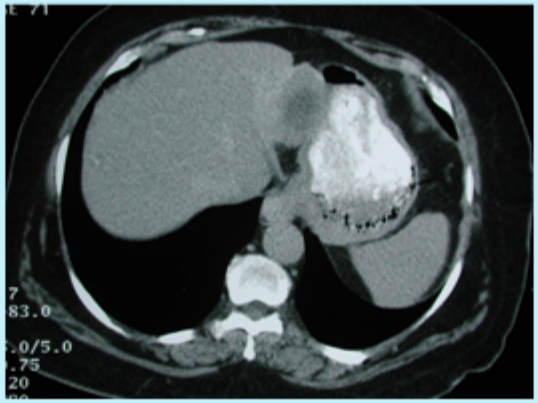

Regenerative nodule located in the gastrohepatic ligament.

Calcified hematoma: following RF ablation of a hepatoma.

Traumatic Laceration

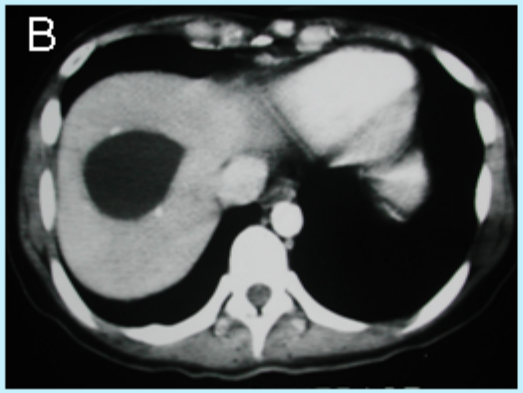

Traumatic biloma (B) following laceration injury to the liver parenchyma (A).

Omental packing: following wedge resection.

Take home points:

- In the liver, common lesions occur commonly.
- Clinical history is extremely important for excluding the spectrum of so-called pseudotumors that occur in the liver.
- Different benign lesions may coexist.
- Benign and malignant tumors may share imaging characteristics.
- Since most lesions are detected incidentally, they are likely to require additional imaging for characterization.
- While cysts and hemangioma's can be confidently characterized, the vast majority of other benign masses have few distinctive imaging characteristics, except for FNH when these demonstrate "classic" features.

Thank you for taking the time to review this exhibit