Beth Israel Deaconess Medical Center

A teaching hospital of Harvard Medical School

Doppler Sonography of the Hepatic Artery Following Liver Transplantation

Jonathan B. Kruskal, MD, PhD
Laurie Sammons, RDMS
Maryellen Sun, MD
Robert A. Kane, MD

Importance of the Hepatic Artery in Liver Transplant Patients

- The biliary epithelium is dependent on its arterial blood supply. Any compromise in arterial blood supply may result in ischemic necrosis of the biliary epithelium.
- After liver transplantation, ischemia resulting from hepatic artery injury may produce sloughing of the biliary epithelium.
- Sloughed biliary epithelium occludes ducts, restricting flow of bile and ultimately compromising hepatocellular function.
- This may progress to failure of the implanted liver, or even complete loss of the graft.

Purpose of Exhibit

- Given the potential significance of hepatic artery abnormalities after transplantation, it is essential to recognize hepatic artery abnormalities as soon as possible.
- Ultrasound with Doppler is typically the study of choice when evaluating arterial flow post transplantation.
- This exhibit illustrates expected hepatic arterial findings after liver transplantation, and details techniques for optimizing the study so as to avoid interpretive pitfalls.
- Examples of the spectrum of common and unusual post-transplant hepatic artery abnormalities are illustrated.

Approach to Imaging the Hepatic Artery in a Transplanted Liver

A series of standard questions should facilitate performance of and interpretation of the hepatic transplant Doppler examination:

- What is the clinical question or suspicion?
- Do the surgeons suspect rejection or vascular compromise?
- When was liver implanted?
- Was this liver from an older donor?
- What was the reason for the transplant?
- Any technical problems during harvesting or implantation?
- Was this an orthotopic or split liver transplant?
- What type of biliary & arterial anastomosis was employed?
- Does the patient have abnormal biochemistry?
- Is the bilirubin level elevated?
- Has the liver been biopsied?
- What other imaging has the patient undergone recently?

Surgical Hepatic Artery Anastomoses

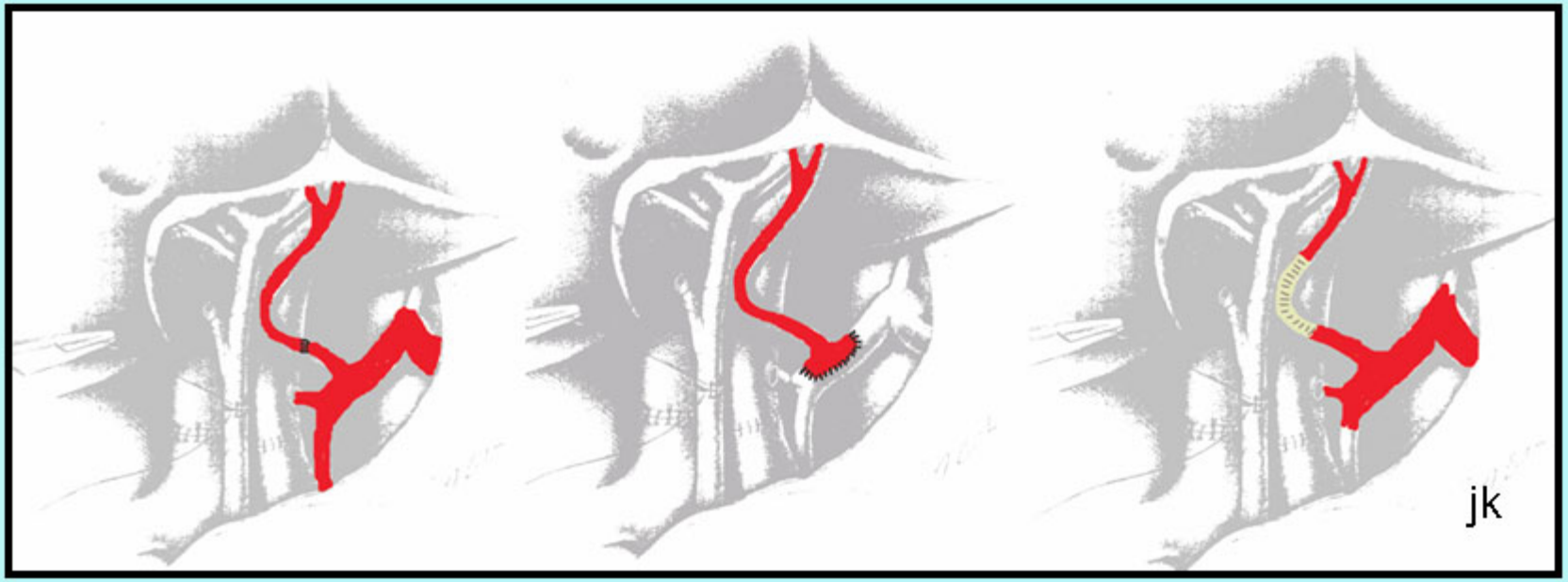

Three broad categories of hepatic artery anastomosis are fashioned during orthotopic liver implantation. These include a direct end-to-end anastomosis (left), a celiac artery patch (middle) or grafts of varying lengths, which may be autologous vascular or even synthetic.

The "Normal" Doppler Appearance of the Hepatic Artery

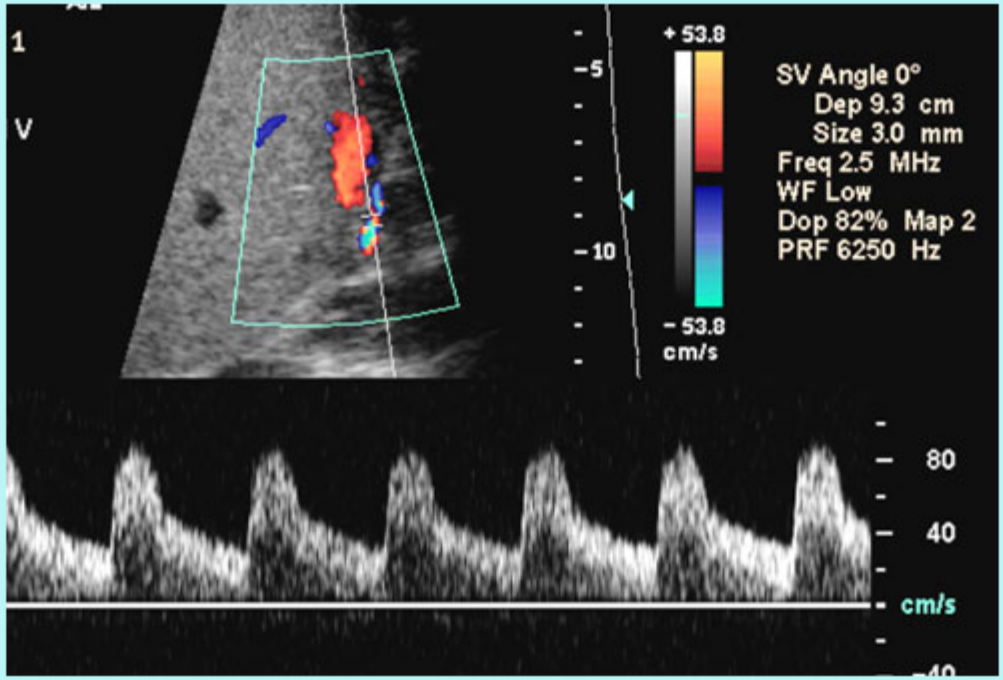

Normal hepatic artery waveform, but not velocity! While this color and spectral Doppler image show a patent artery with a normal spectral waveform, the lack of angle correction does not permit us to accurately measure the peak flow velocity. Note the normal brisk systolic upstroke and down slope with little spectral broadening, and antegrade flow throughout diastole. In the transplant patient, arterial flow must be characterized in the main, left and right hepatic arteries.

Optimize the Doppler parameters: the importance of the angle of insonation.

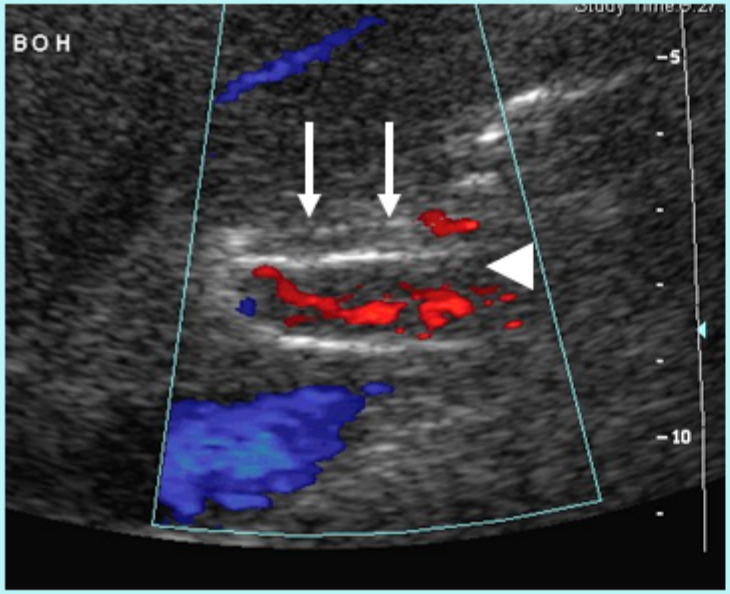

This image of the portal vein shows what appears to be non-occlusive mural thrombus in the portal vein (arrowhead), with *no appreciable flow in the hepatic artery (arrows)*. Note that the vein is perpendicular to the transducer (cosine of 90 degrees = 0) resulting in no hepatic artery flow being visible.

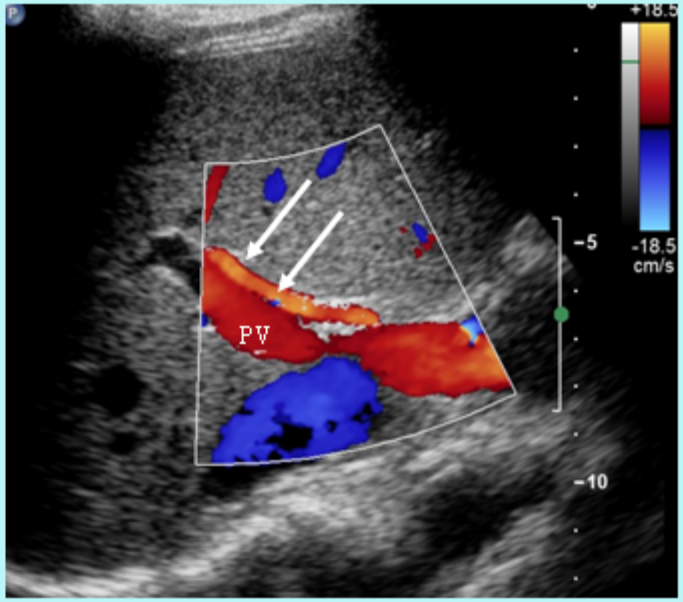

By adjusting the angle of insonation to be between 30 and 70 degrees (in this same patient), normal vigorous wall-to-wall flow is shown in the widely patent portal vein (PV), and in the adjacent hepatic artery (arrows).

Angle correction

In order to accurately determine flow velocity, angle correction must occur. These examples illustrate the effects of no correction, or overestimating the flow direction.

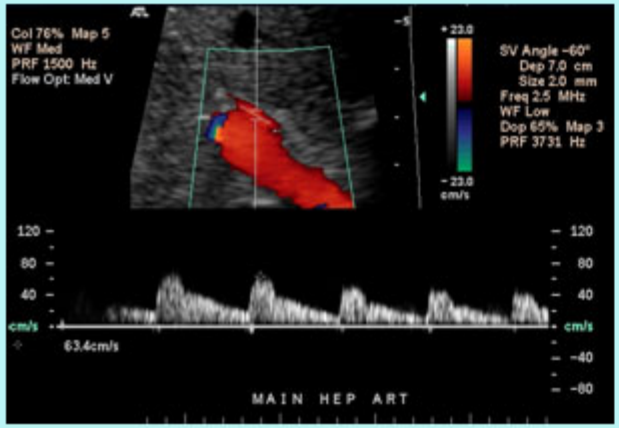

In this transplant patient with suspected stenosis of the HA, the corrected velocity (image above) measures 63.4 cm/sec.

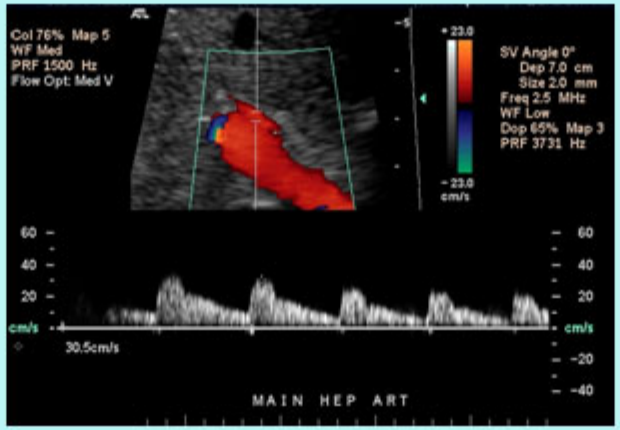

In the same patient when no angle correction is performed (above), the calculated velocity is 30.5 cm/sec, grossly underestimating flow.

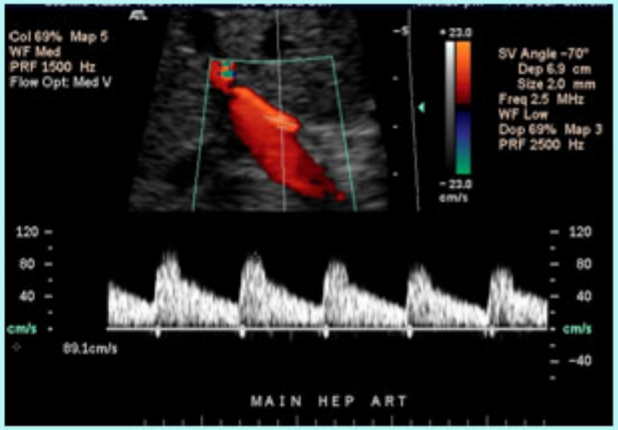

When the angle correction is overestimated (above) the calculated velocity is 89.1 cm/sec, grossly overestimating flow.

False positive arterial patency!

It is very important o document arterial flow both in the main hepatic artery, as well as in the intrahepatic left & right hepatic arteries. The example below shows how interpretive errors can occur.

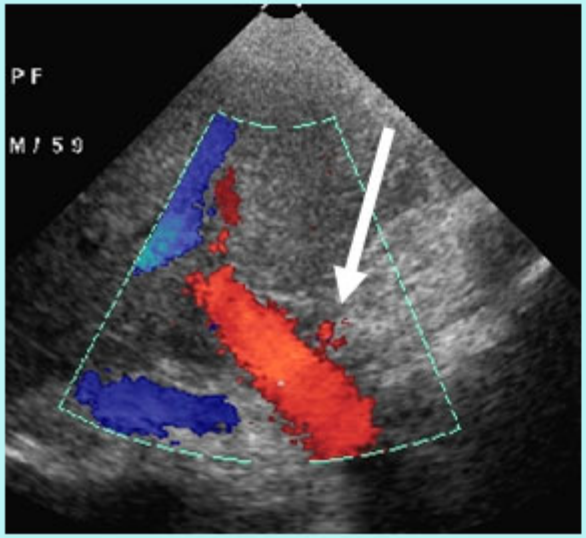

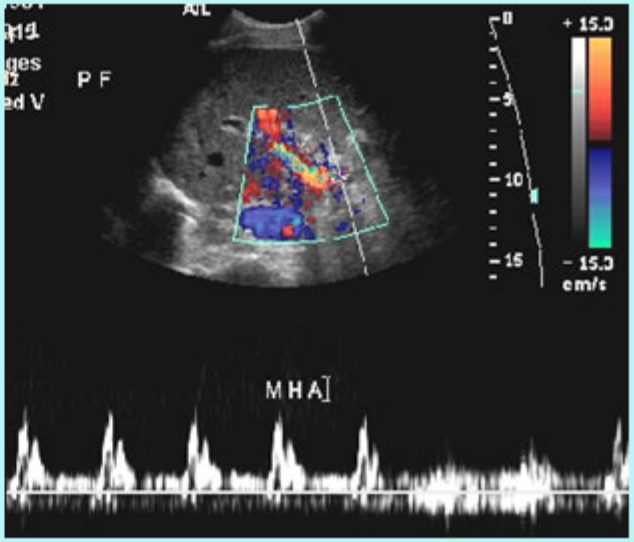

This color Doppler image shows a patent portal vein with antegrade flow, and apparent flow within the adjacent hepatic artery lying anterior to the portal vein (arrow) in the hilum of the liver.

The technologist obtained a spectral waveform and even labelled the main hepatic artery (MHA). However, clinical concerns led to an angiogram being obtained which showed an occluded MHA – all flow was diverted into the gastroduodenal artery (GDA).

False positive arterial patency!

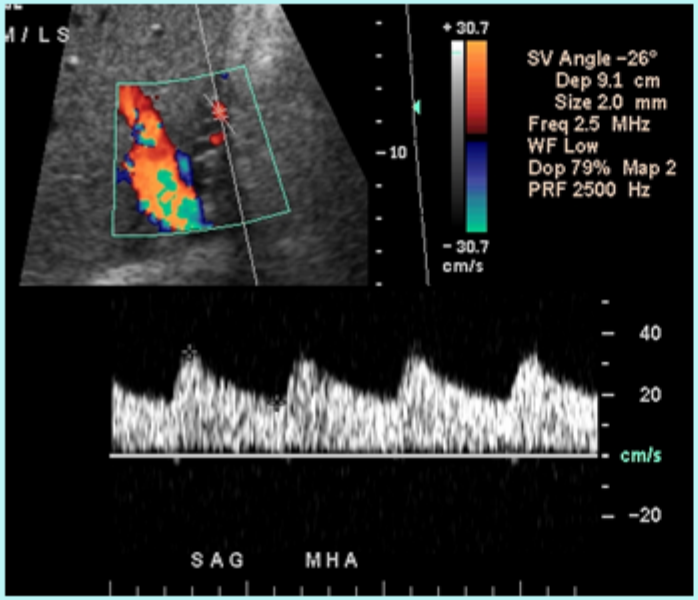

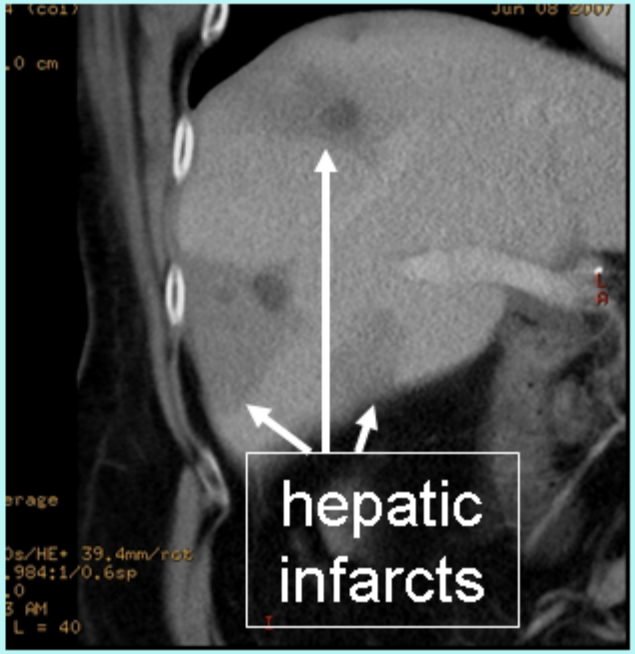

In the Doppler image above, the technologist believes he has interrogated the main hepatic artery (labeled MHA). Note the distance between this artery and the portal vein. This is really the gastroduodenal artery (GDA) in a patient with an occluded HA as shown on CT angiograms on the right. This case illustrates the importance of always documenting patency of the intrahepatic arteries.

Why can't the HA flow velocity be measured?

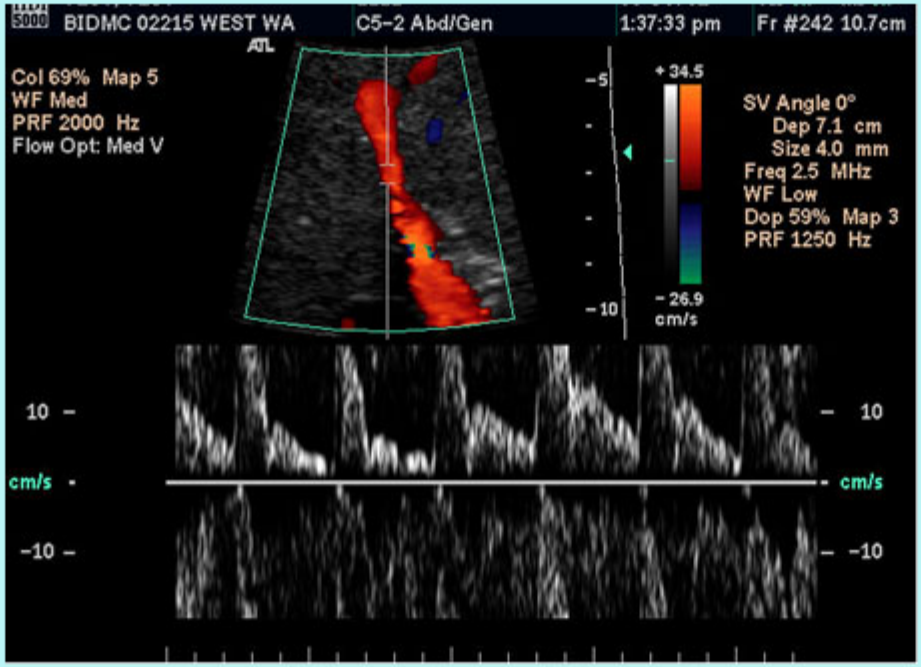

In this example, aliasing of the HA waveform is present and no accurate velocity can thus be measured. Note that the scale is low (range -26.9 to +34.5 cm/sec). By increasing the frequency of acquisition or range of velocities that are sampled (by increasing the velocity scale or Pulse Repitition Frequency), aliasing will be eliminated.

Main Hepatic Artery Occlusion

With hepatic artery occlusion, flow is usually absent in the porta hepatis. However, if flow is identified in the porta hepatis this may be from flow in the patent GDA or in collateral vessels. A tardus parvus waveform may be detected when the resistance to inflow is sufficiently high to be functionally occluded.

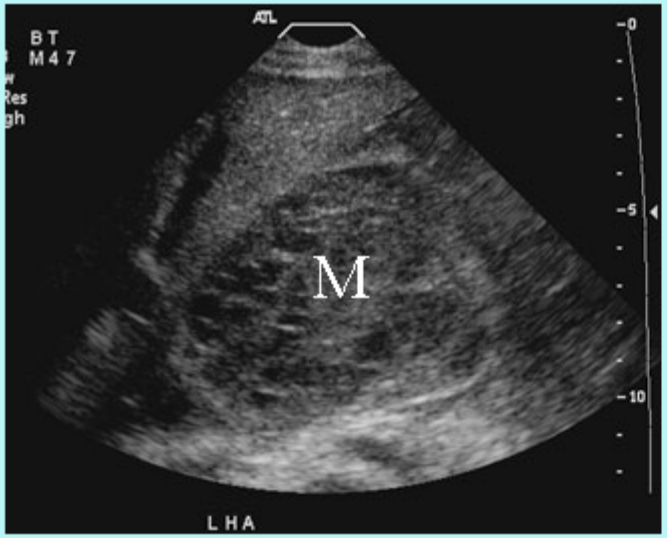

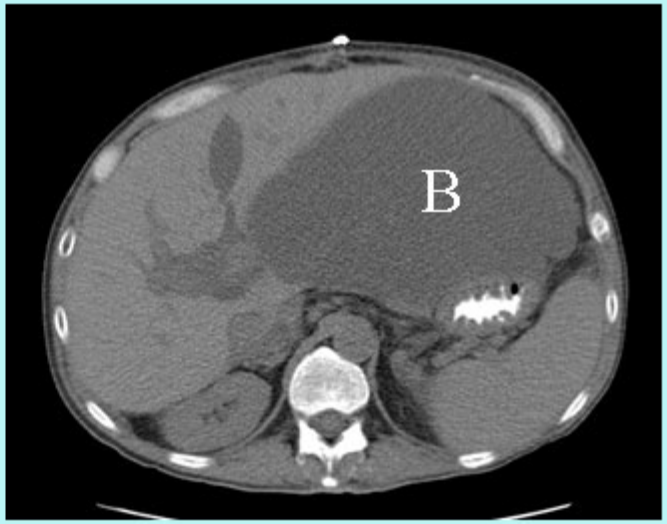

In these images from the liver of a patient with main HA occlusion, a large complex mass is identified inferior to segment III on ultrasound. CT scan confirms this to be a large biloma (B) from bile duct rupture secondary to ischemia.

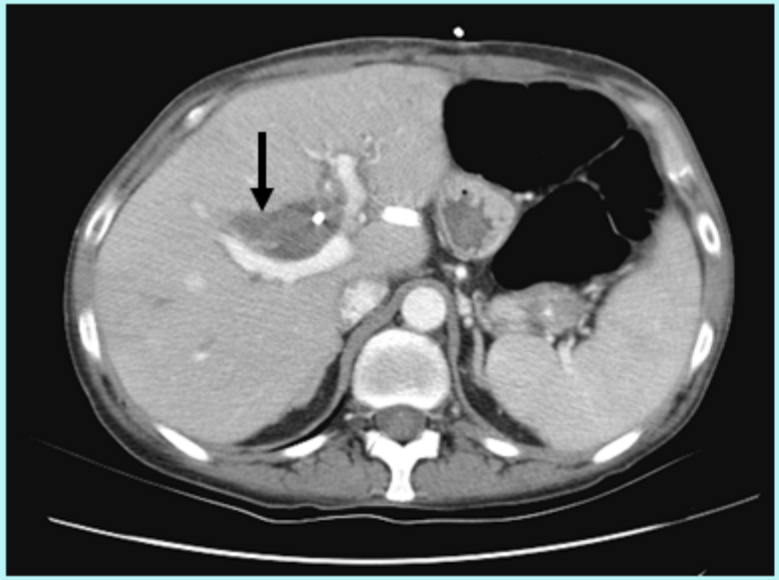

In this transplant patient, occlusion of the right hepatic artery resulted in ischemic necrosis of the right hepatic duct (arrow; CT left). On ultrasound, the sloughed biliary epithelium appears as a solid echogenic mass within the dilated bile duct (arrow below). Note the biliary catheter traversing the “mass” in the middle image below.

US and CT appearances of sloughed bile duct mucosa

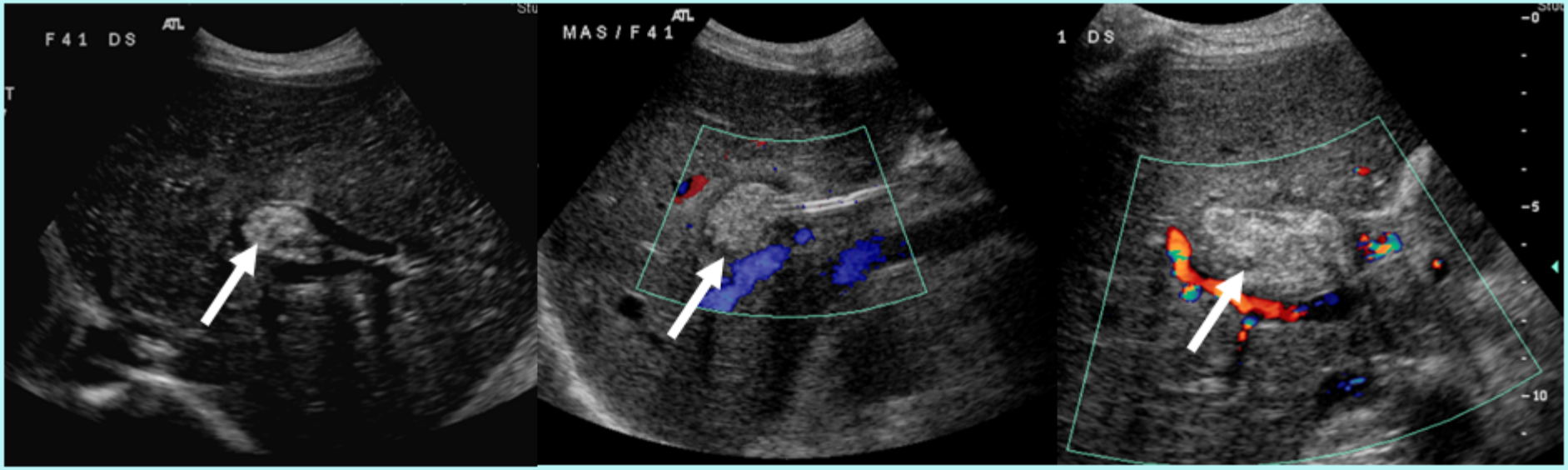

Occluded Left Hepatic Artery

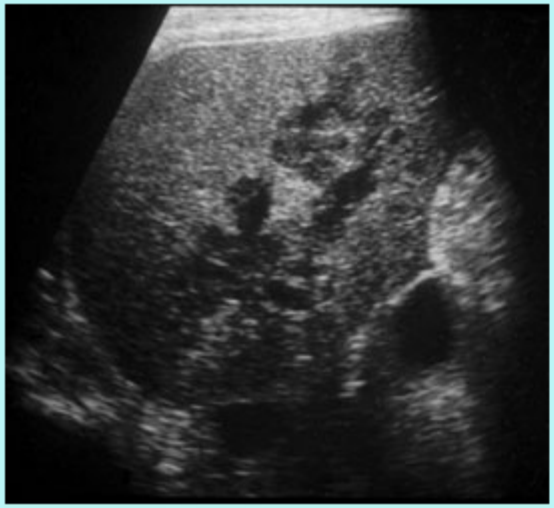

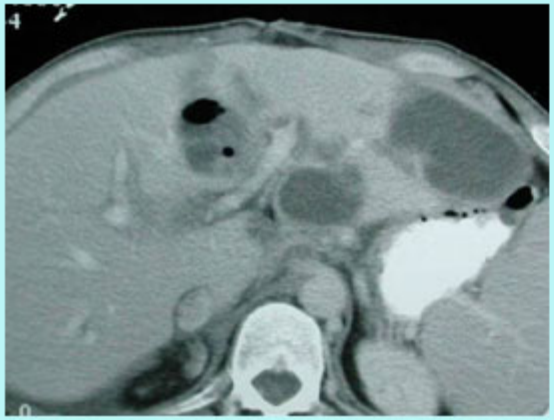

These gray scale US and correlative CT scan images show 2 different manifestations of an occluded left hepatic artery. During early post-occlusion, the bile ducts appear as tubular hypoechoic branching structures (top left). With progression, the entire left lobe develops an extremely abnormal architecture (top right). Note that with subsequent tissue necrosis, gas is released and has a similar appearance to an abscess on CT scans (bottom images).

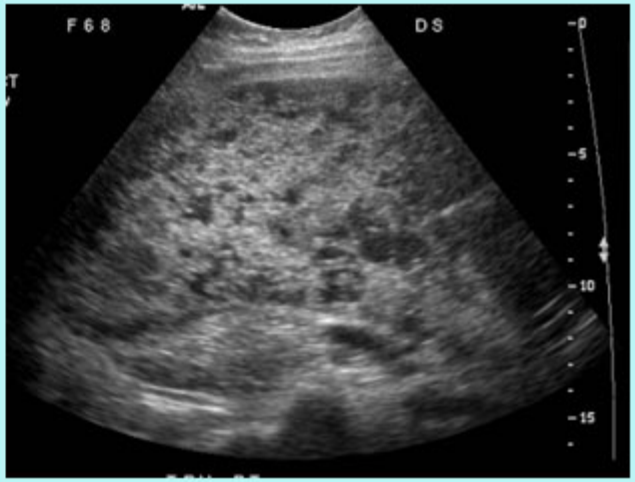

Why is the hepatic artery flow reversed?

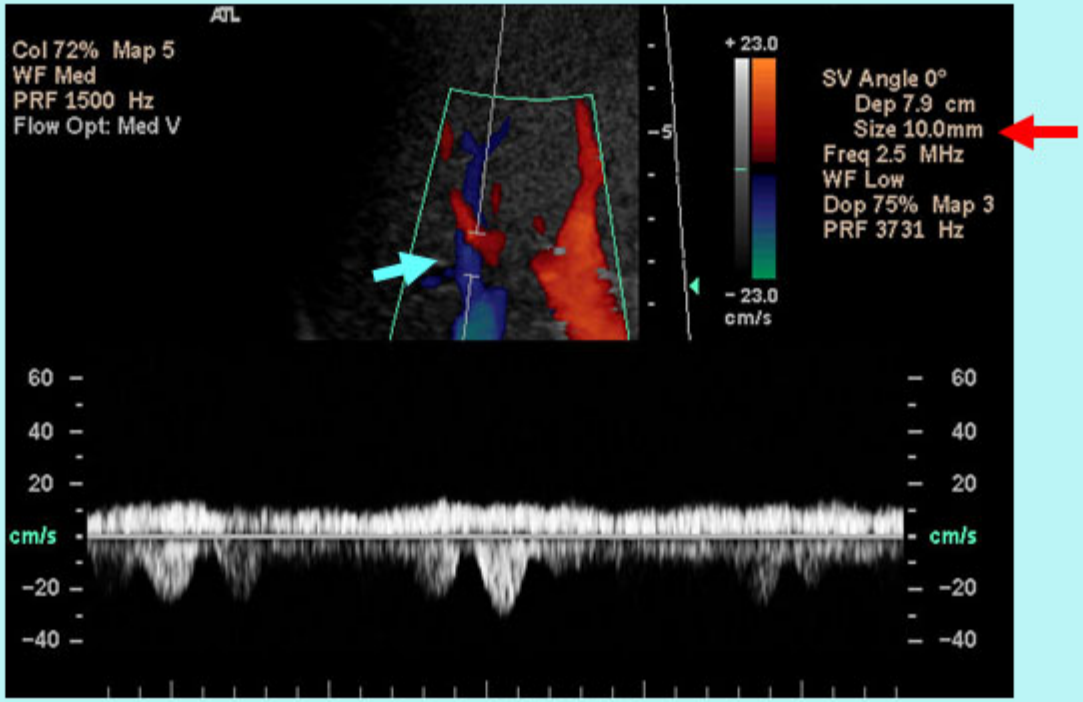

This color and spectral Doppler image demonstrates what happens when the sampling gate is too large. In this example, a 1cm (red arrows) gate is used resulting in flow being sampled from 2 adjacent vessels. This superimposed flow falsely suggests hepatic arterial patency. In this example, the 1cm gate (blue arrow) is sampling from both the portal vein (red flow above spectral baseline) and the hepatic vein (blue flow beneath spectral baseline).

Why is hepatic arterial flow occurring both away from and towards the transducer?

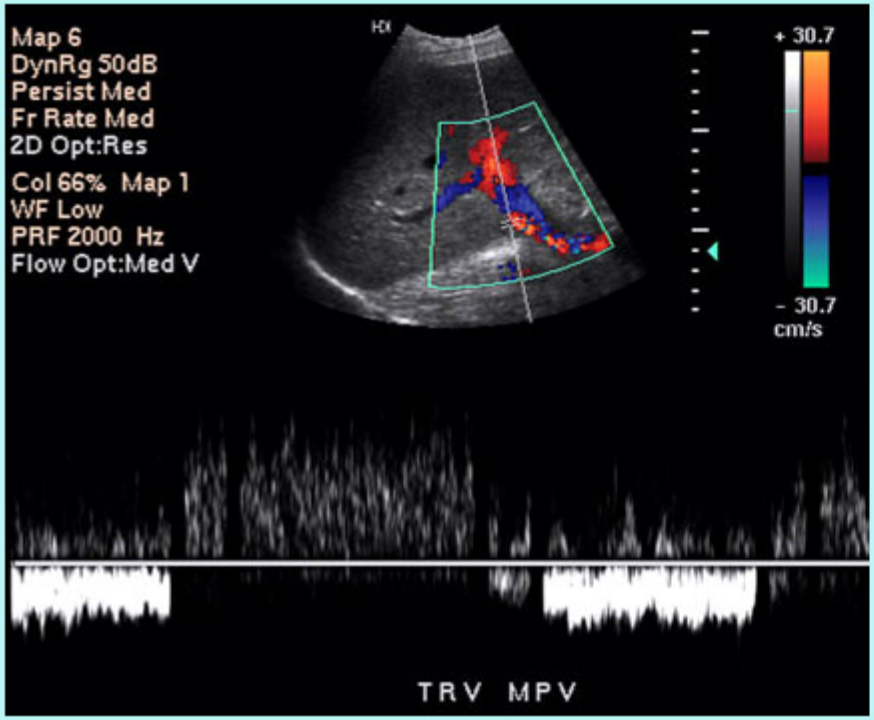

This color Doppler image appears to show 2 parallel vessels in the liver hilum, suggesting possible reversal of portal venous flow. In the transplant patient, this is a common finding and is simply due to helical flow in the portal vein following end-to-end anastomosis. (Rosenthal SJ et al. Doppler US of helical flow in the portal vein. *RadioGraphics*. 1995;15:1103-11)

This color and spectral Doppler image shows normal expected turbulent and helical flow in the portal vein. This is NOT the hepatic artery that is being sampled, or reversal of portal flow. The appearance of this too-and-fro helical flow is an expected finding in transplanted livers.

Hepatic Artery Stenosis

Most hepatic artery stenoses develop at the site of anastomosis, and are typically related to the complexity of the surgical technique. Stenoses may be also be caused by clamp injury during surgery, by dissection, by disruption of the vasa vasorum in the arterial wall causing ischemia, or by rejection.

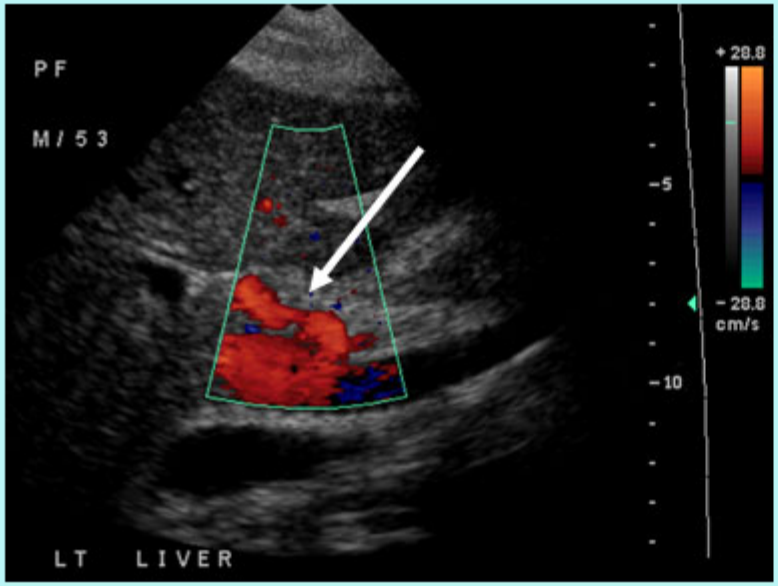

This color Doppler image (left) shows a focal stenosis of the hepatic arter (arrow), shown also on the CTA (arrow, right image).

Tardus Parvus Waveform

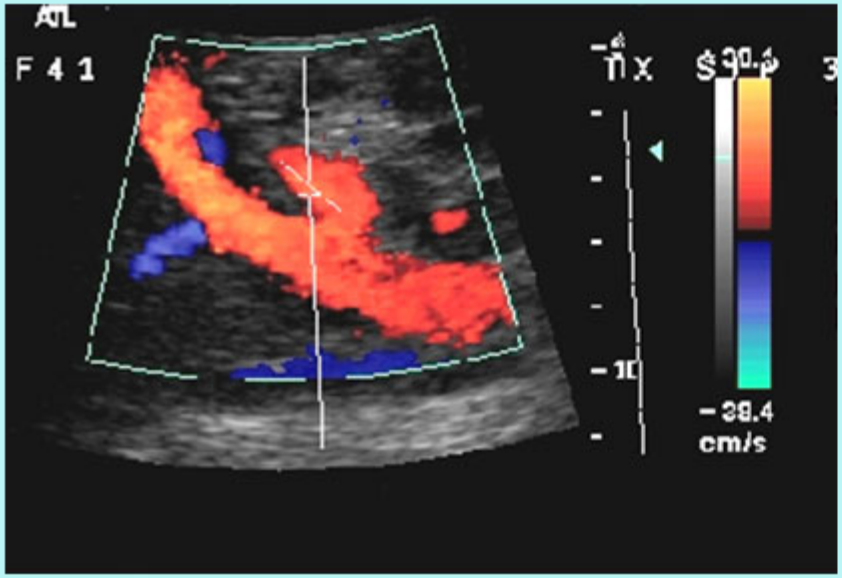

Definition of Tardus Parvus Waveform:

- Resistive Index < 0.5
- Systolic acceleration time > 0.1sec
- Best indicator of HA stenosis
- 91% sensitive, 99% specific
- False positive causes:
  - Diffuse hepatic edema
  - Severe rejection
  - Hemorrhage

Vit et al; JCU 2003; 31: 339

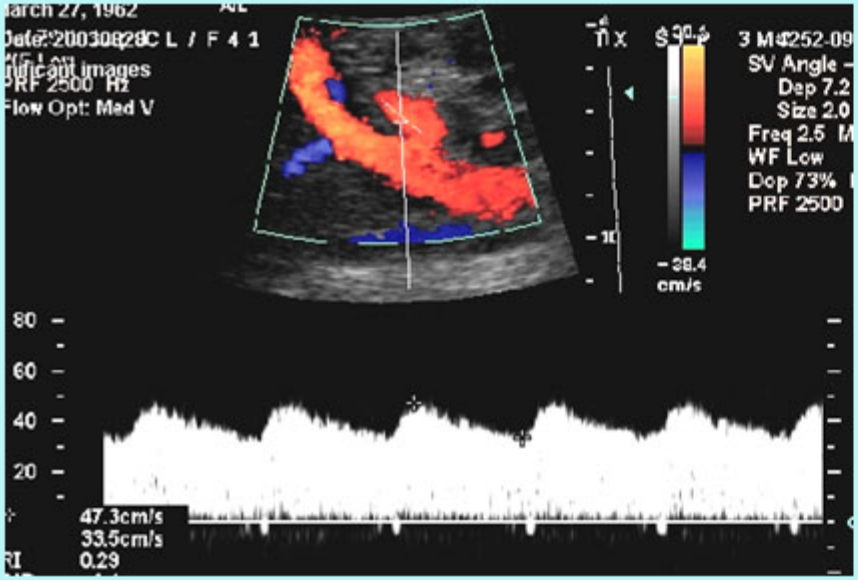

Whereas the color Doppler study shows widely patent hepatic artery in this transplant patient (top image), the abnormal "tardus parvus" waveform below, with characteristic slow upslope, spectral broadening and low resistive index, is highly suggestive of a stenosis of the hepatic artery.

Tardus Parvus Waveform

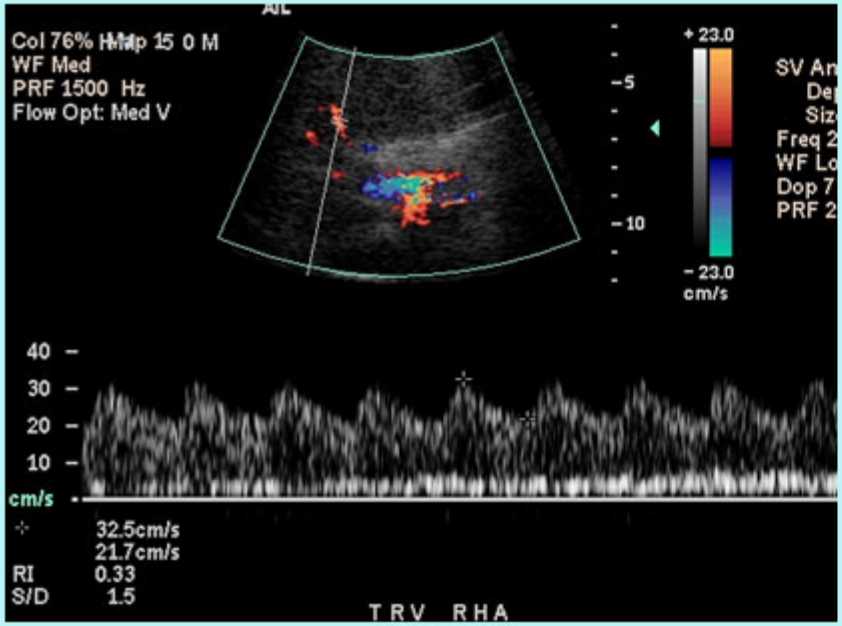

The measured RI in the hepatic artery of this transplant patient is 0.33 consistent with a tardus parvus waveform. Even though no angle correction has taken place, waveforms are independent of angle correction and this waveform indicates HA stenosis.

Based on this abnormal waveform, the patient underwent an angiogram which shows a tight stenosis at the anastomosis (arrow). This was stented and the waveforms returned to normal within 1 week.

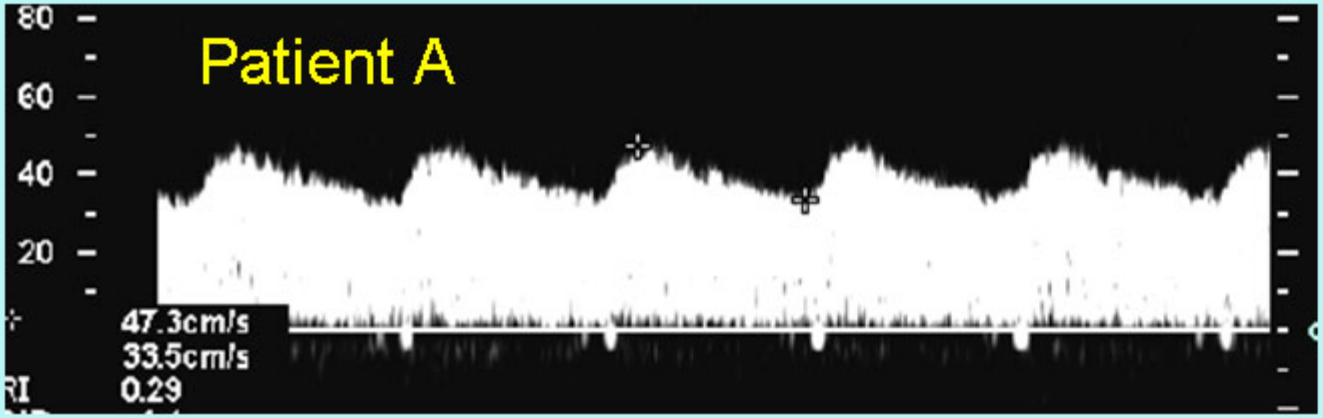



Which Arterial Stenosis is Worse – Patient A or B?

Both of these spectral Doppler waveforms show a tardus parvus pattern due to hepatic artery stenosis. The peak systolic velocity is greater in the patient A shown at top (47.3 cm/sec). The velocites cannot be used to compare waveforms from these 2 patients since it is not know where the artery was sampled relative to the site or type of anastomosis. If the graft is >72hrs old, additional angiographic imaging is suggested to characterize and treat the likely hemodynamically-significant stenosis.

The post-transplant HA waveform depends on the sampling site

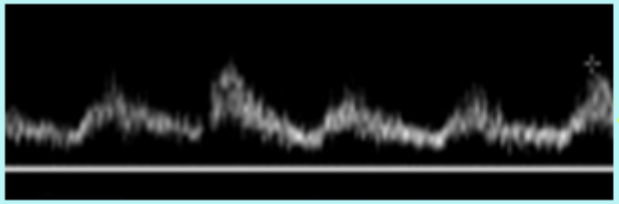

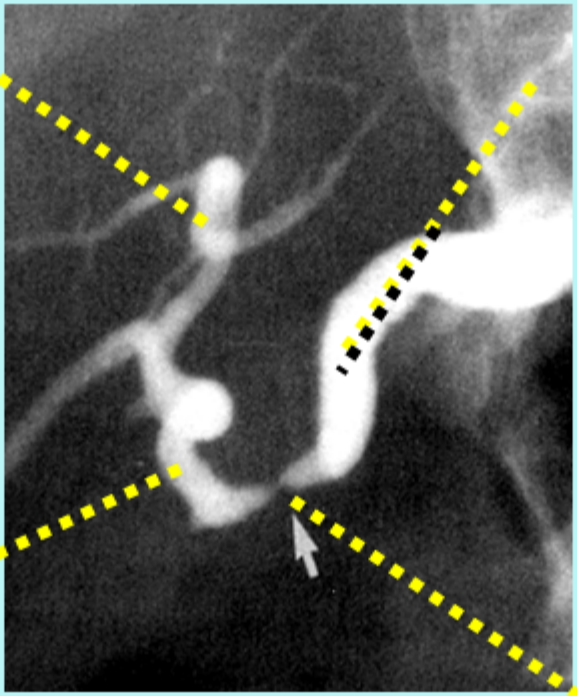

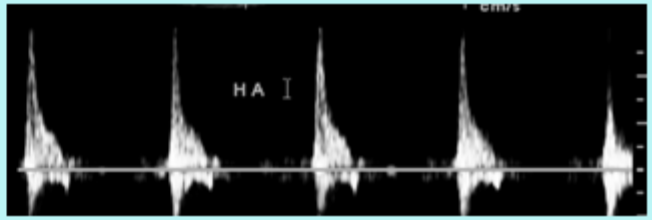





In the transplanted liver, the spectral waveform depends largely on the precise location where spectral sampling takes place. In these examples in a patient with HA stenosis (best shown bottom right), different waveforms are illustrated and are correlated with the location of sampling relative to the site of the stenosis. Note the more uniform velocities the further one samples from the site of stenosis.

Segmental Hepatic Artery occlusion

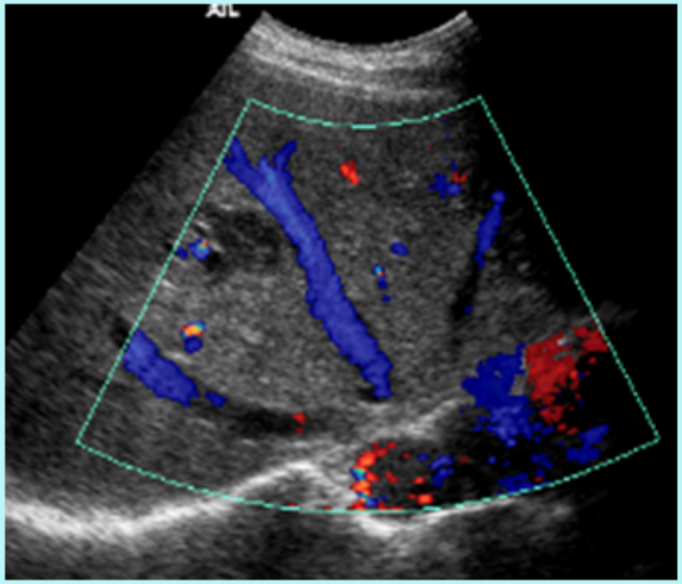

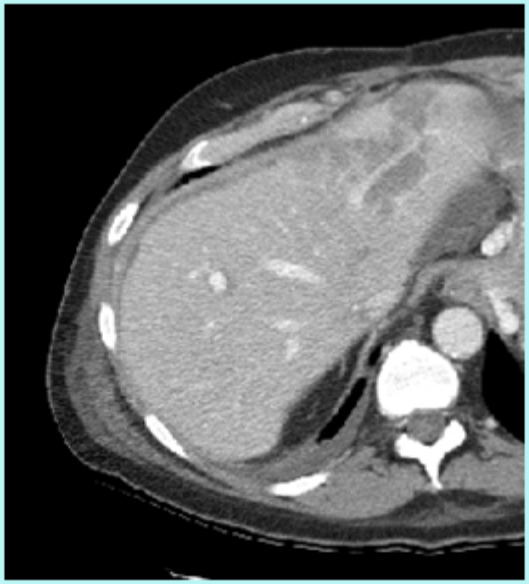

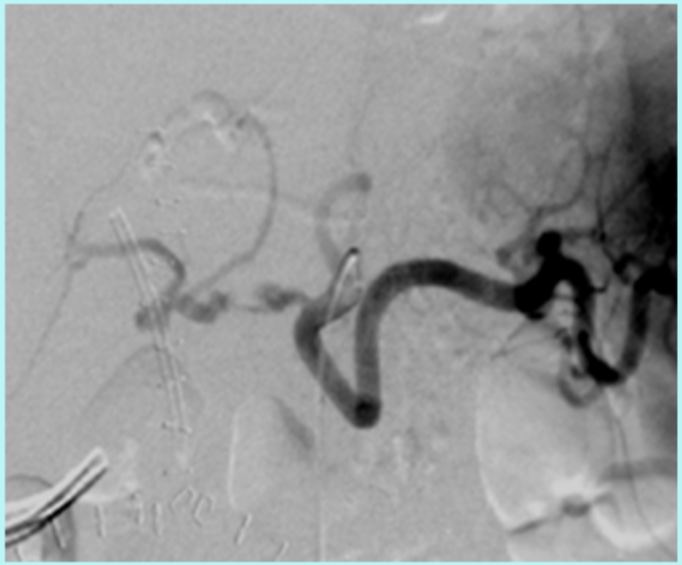

These images show the ultrasound and CT features of segmental occlusion of the main hepatic artery (shown in angiogram, bottom left). Both on US and CT, small focal areas of under perfusion are noted either centrally or peripherally, and these can typically be identified along with adjacent widely patent portal or hepatic veins.

High resistance hepatic arterial flow

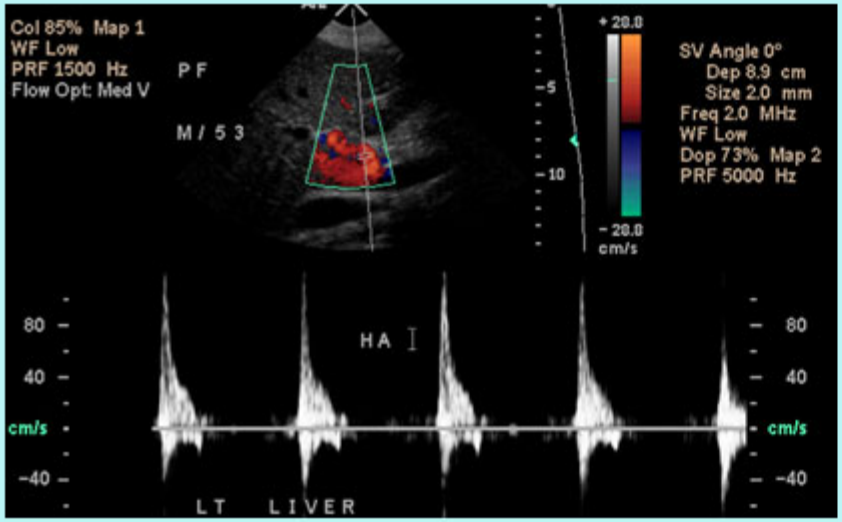

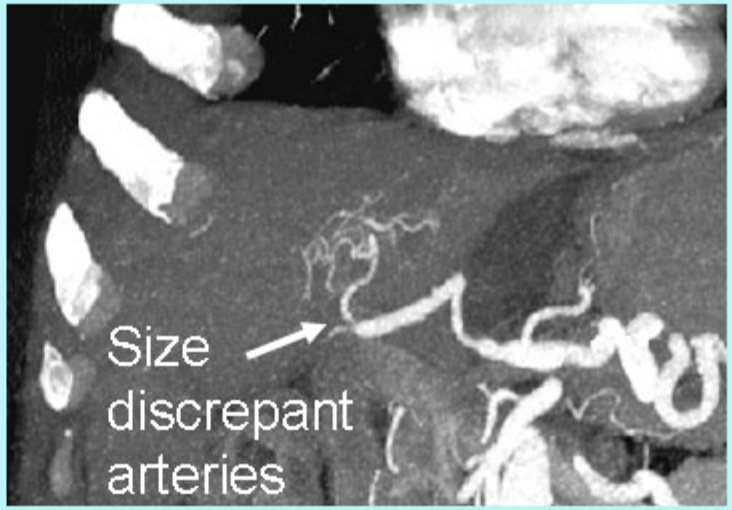

On the spectral waveform, high resistance flow in the hepatic artery manifests as peaked systolic waves with brisk upslope and downslope. In this example, note also the absence of antegrade flow during diastole.

High Resistance Flow may be a normal finding in the first 72 hrs post implantation. Other causes include: *older donors, prolonged preservation, size discrepant grafts or arteries (example above) , acute rejection, splenic artery steel, and HA spasm, dissection or stenosis.*

Acute Rejection of the Transplanted Liver

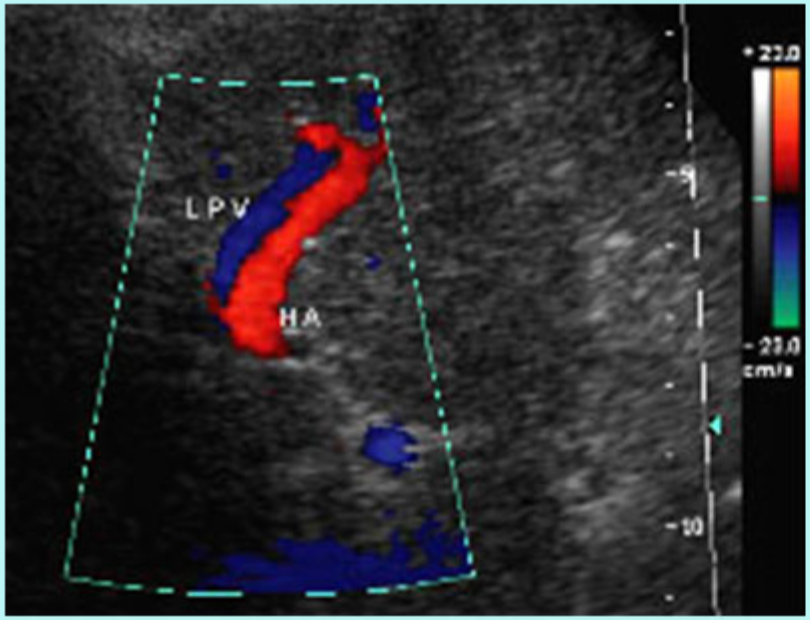

This color Doppler image in a patient 2 hours post implantation, shows reversal of flow in the left portal vein (LPV) with expected flow direction in the adjacent hepatic artery (HA). This reversal of flow developed due to *acute rejection* in this implanted liver. A similar appearance may be a *normal finding following successful TIPS* stent insertion.

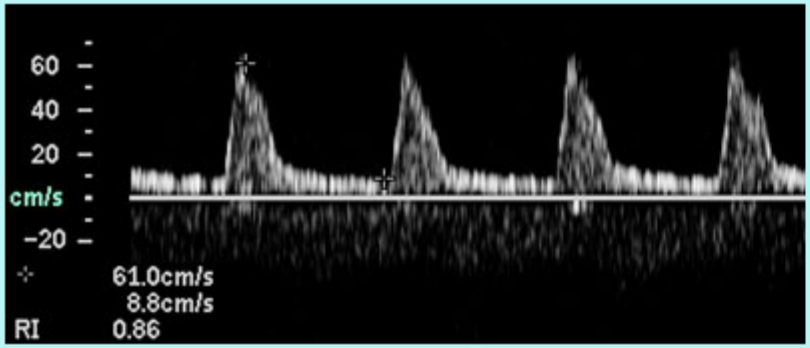

The spectral waveform (above) in this transplant patient shows an elevated RI of 0.88 with brisk systolic upslope.

This spectral Doppler waveform, obtained in the patient shown above, demonstrates features consistent with resistance to arterial inflow. Note the peaking of the systolic waves and absent flow during diastole.

High resistance flow in Cholangitis

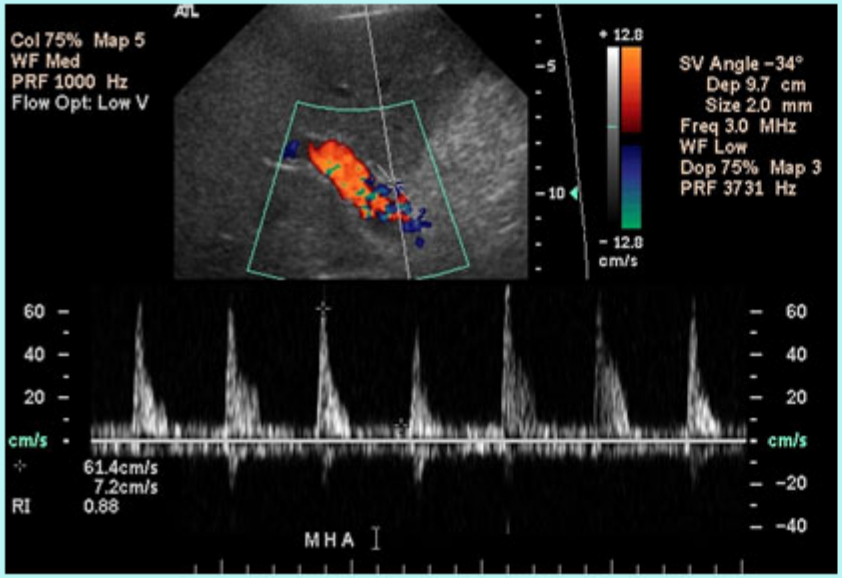

Diffuse or even segmental parenchymal disease of the liver can restrict hepatic perfusion and produce high resistance flow in the hepatic arteries. In this example, multi-segmental cholangitis has developed post transplant, resulting in peaked systolic waveforms on Doppler (left). Note the characteristic perfusion anomalies on the CE-CT scan (right).

Reversal of Flow in Hepatic Artery

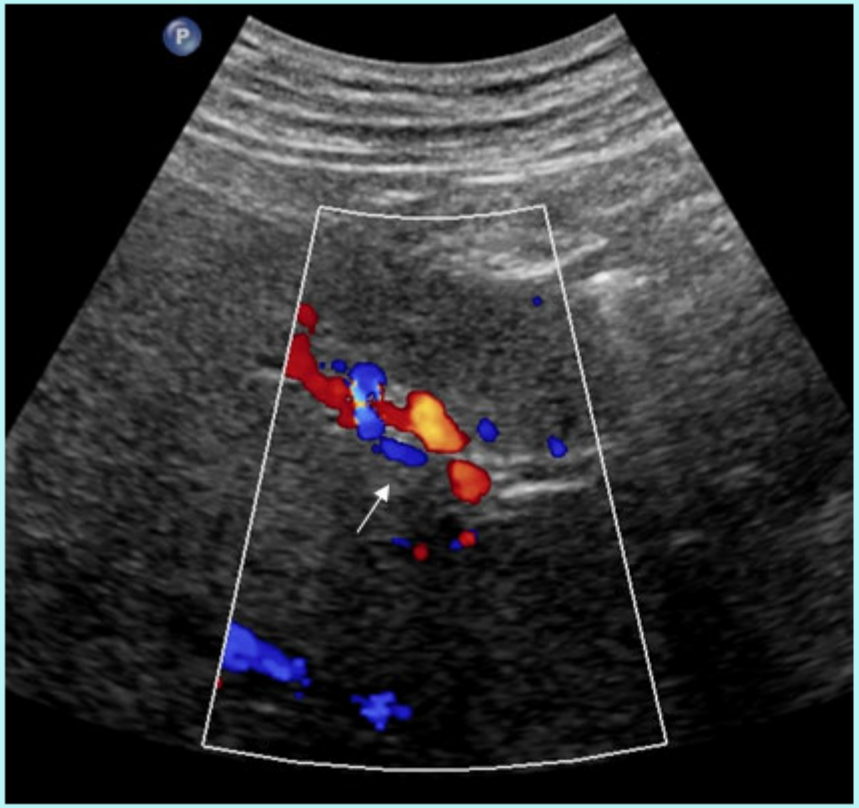

This color Doppler image of a liver transplanted 12 months previously shows reversal of flow (arrow; blue indicates flow away from transducer) in the main hepatic artery. Focal occlusion of the hepatic artery after transplantation may result in formation of collateral vessels reconstituting the more distal HA. When this occurs, focal segments with reversed flow can be identified (AJR 2008; 191: 546-9)

Splenic Artery Steal Syndrome

In patients with the splenic artery steal syndrome, preferential arterial flow occurs away from the liver into the splenic artery. Flow may also occur into the gastroduodenal artery. The liver may suffer devastating consequences from the ensuing hypoperfusion. On Doppler, diminished flow is seen in the hepatic artery while CT or MRI are more likely to show secondary signs of hepatic hypoperfusion. Angiography is currently the diagnostic test of choice (contrast flows preferentially into the splenic artery following celiac artery injection), since the steal is treated by transcatheter occlusion of the splenic artery.

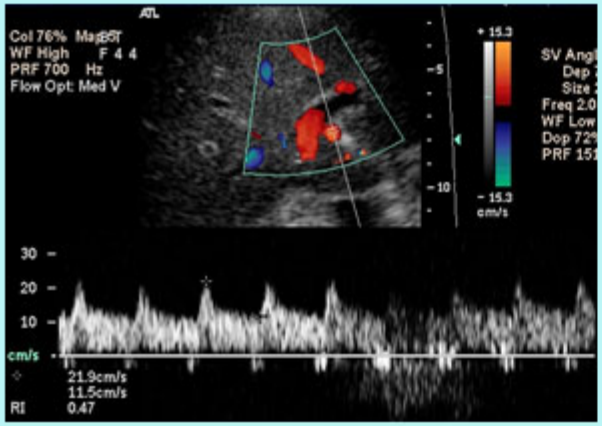

These images show low velocity (21 cm/sec) flow in the HA (left) with preferential flow into the splenic artery on the CT angiogram.

The splenic artery steal phenomenon remains **controversial**, since many abnormalities of the hepatic artery that occur after transplantation (stenosis, thrombus formation, dissection, or occlusion) will cause preferential flow into the splenic artery as well.

Renan et al. Cardiovasc Intervent Radiol, 2002; 25: 300-6

Influence of underlying cardiac disease on the Hepatic Artery waveform

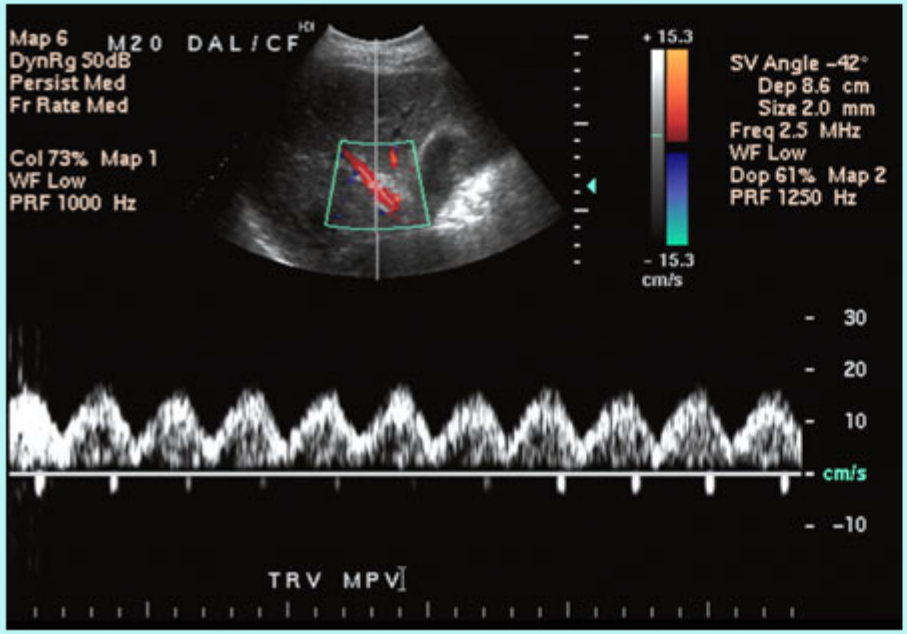

In this liver transplant patient with an ethanol-associated dilated **cardiomyopathy**, the spectral Doppler waveform shows an undulating to-and-fro pattern resulting from transmission of cardiac systolic pulsations through the liver and into the portal vein. Following biopsy, careful attention may be required to distinguish this finding from a central arterio-portal fistula.

These spectral waveforms in 2 patients with cardiomyopathy demonstrate the regular periodicity of the arterial-appearing waveforms, which may even show reversal (flow below baseline/away from transducer) during the latter phase of the cardiac cycle (top image).

Iatrogenic Arterioportal Fistula

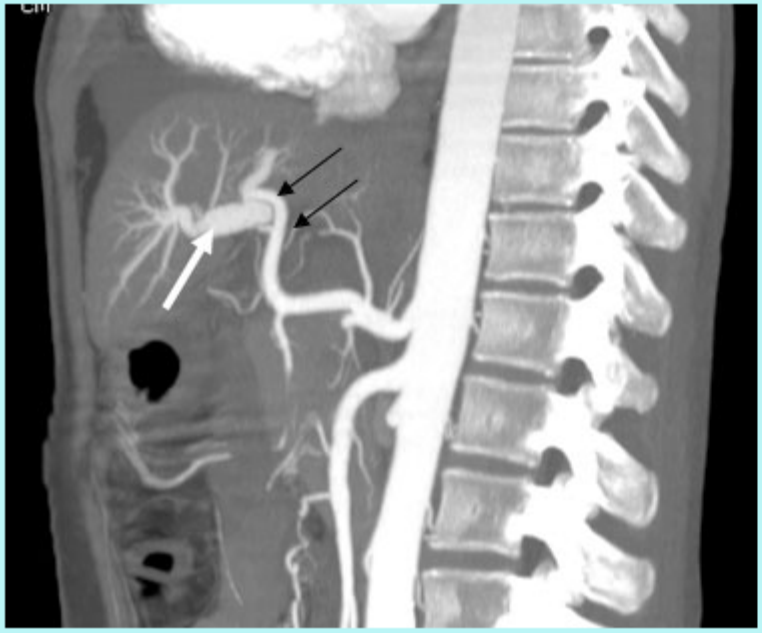

This sagittal image from a contrast-enhanced CT scan in a transplant patient shows brisk communication between the main hepatic artery (small black arrows) and the portal vein (white arrow). This occurred as a result of a percutaneous biopsy.

Communications between the hepatic artery and portal vein are usually iatrogenic, most commonly resulting from percutaneous biopsy or insertion of biliary catheters. Such fistulas are typically peripheral rather than central, the vast majority spontaneously closing and of no clinical significance. When these are hemodynamically significant, and liver failure occurs, the communication requires closure, usually via embolization.

False negative arterial patency

This contrast-enhanced CT scan shows hemorrhage (arrows) encircling the patent hepatic artery anterior to the portal vein anastomosis (white arrow). Such soft tissue around the small hepatic artery is one cause of “no” flow being detected on Doppler sonography.

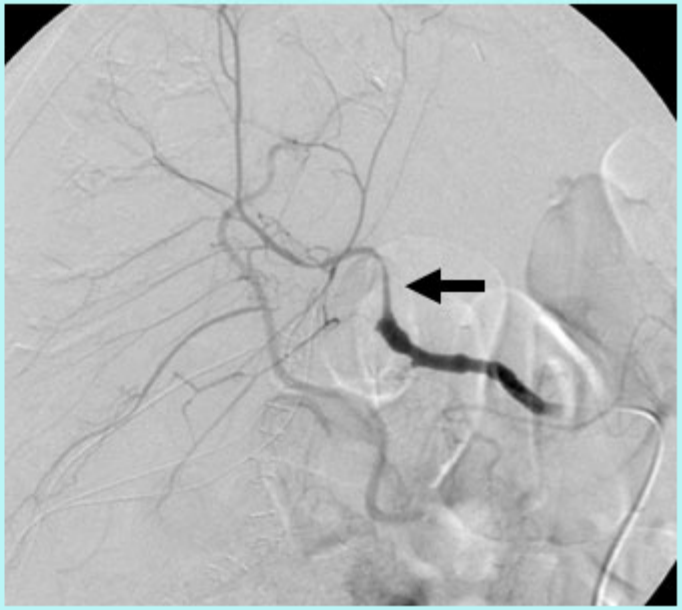

This patient underwent a right lobe grafting with 3 separate arterial anastomoses to the recipient main hepatic artery. The angiogram shows a patent hepatic artery (arrow) supplying the graft but the operators were unaware at the time that 2 intrahepatic arteries were not demonstrated.

Hepatic Artery Stabilizer Ball



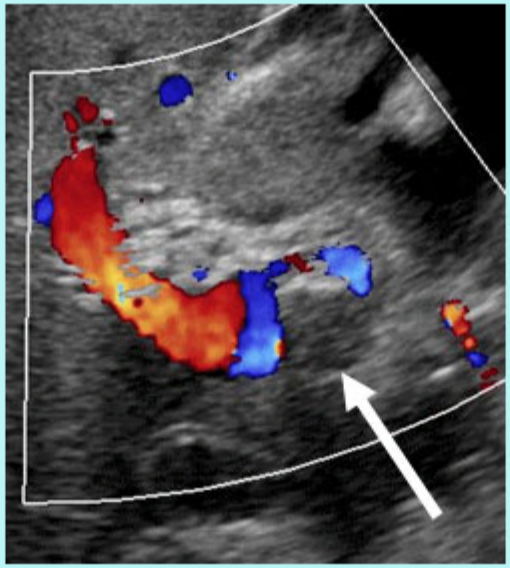

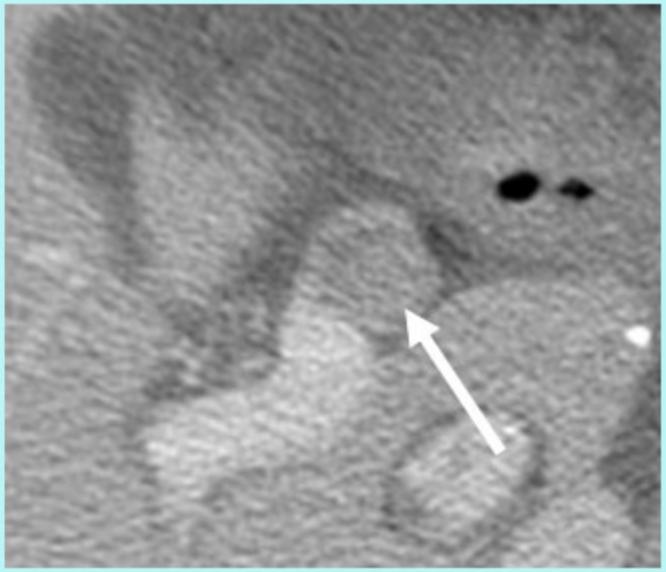

When hepatic artery jump grafts are employed, or a long tortuous artery results after anastomosis, kinks may develop restricting inflow. In this setting, some surgeons insert stabilizer devices. In this example, a surgicell sponge (top left) has been inserted behind the hepatic artery (arrow, middle image). The sponge should not be mistaken for a lymph node or portal vein thrombus.

Hepatic Artery Pseudoaneurysm

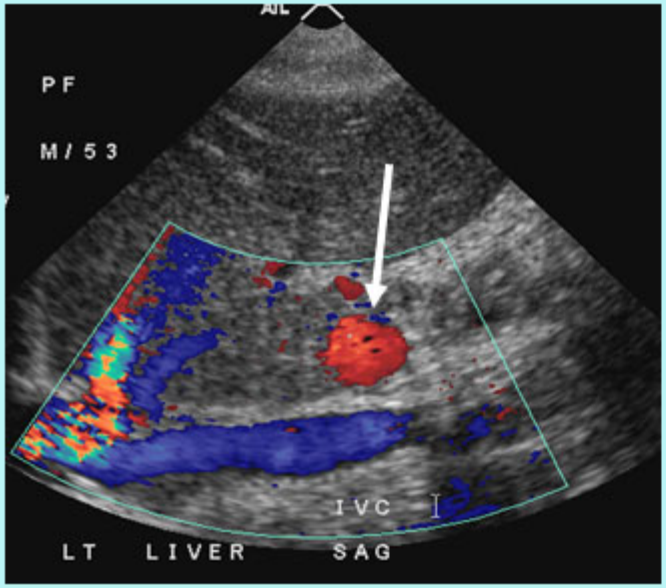

This images demonstrate a 1cm pseudo aneurysm of the hepatic artery (arrows) which developed at the site of anastomosis.

Two types of pseudoaneurysms occur after transplantation; intraparenchymal aneurysms typically occur post procedure (biopsy, RF ablation, PTC etc) whereas hilar aneurysms often occur at or near the site of anastomosis and are often incidental unexpected findings on imaging studies.

Hepatic Artery Pseudoaneurysm

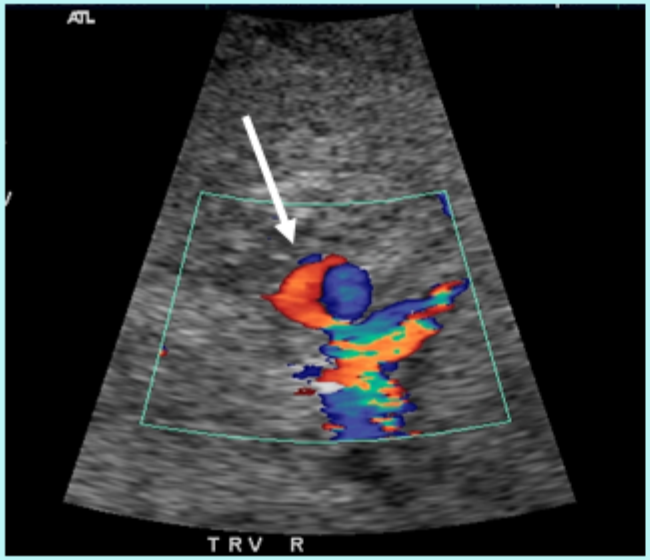

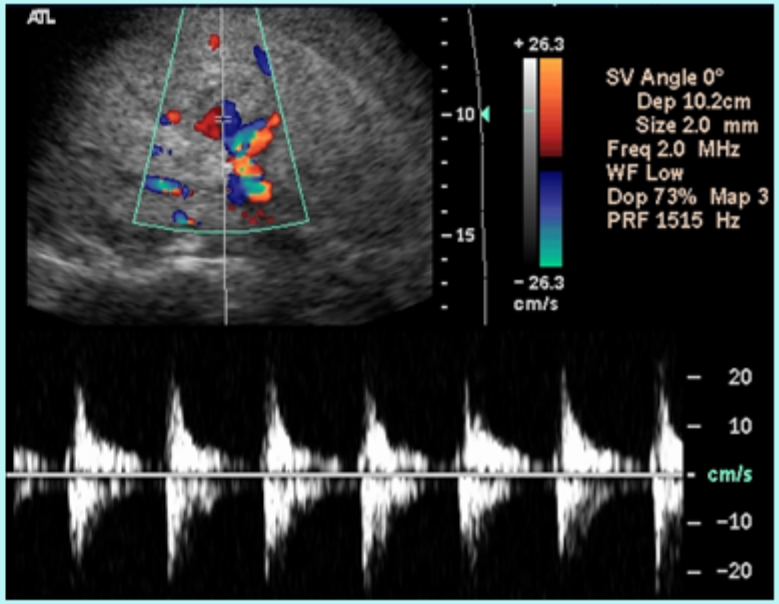

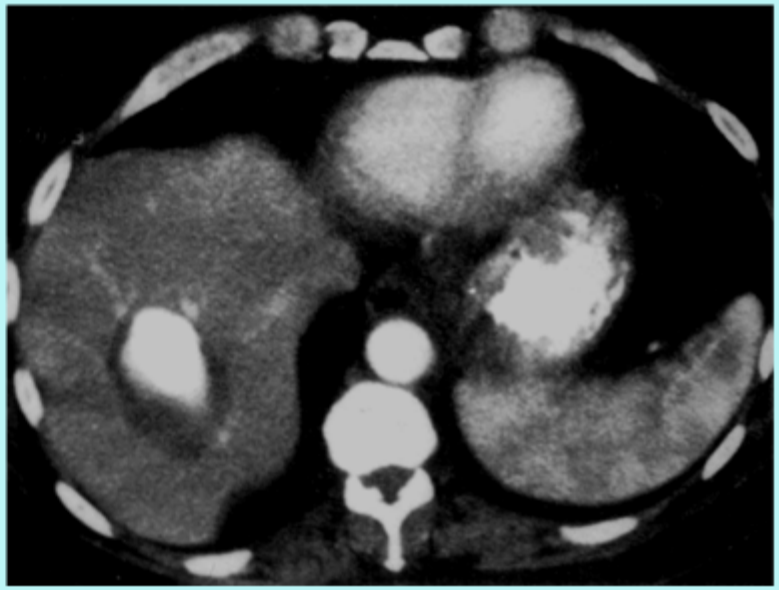

Color (above) and spectral Doppler (top right), and CT scan demonstrate a 2cm pseudoaneurysm that developed post RF ablation. Note the too and from flow on color Doppler (arrows) and on the spectral waveform.

Dissection of the Hepatic Artery

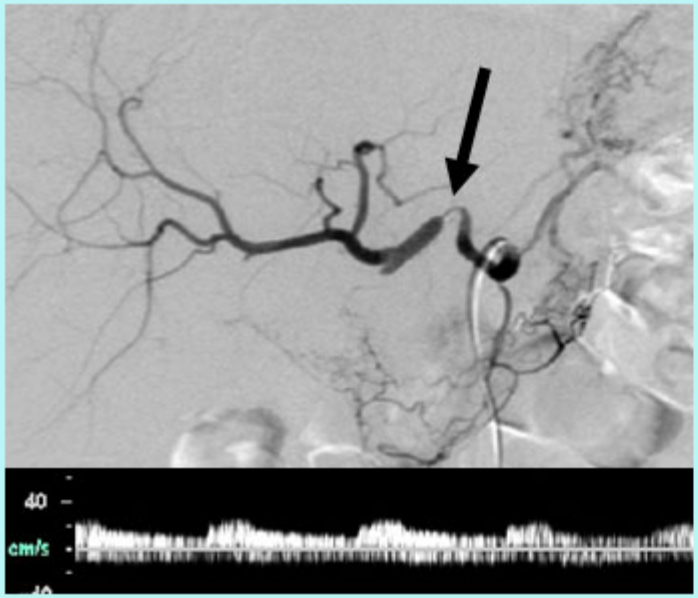

During balloon dilation (white arrow, left) of hepatic artery stenosis near the anastomotic site (black arrow, left) in this transplant patient, a catheter injury occurred causing a focal non-occlusive dissection to occur. Note the tardus parvus waveform (image below left) indicating compromise to arterial inflow. The CT images show the dissection (middle image) and the large segmental infarct that developed (right image).

Venous flow wrongly ascribed to Hepatic Artery

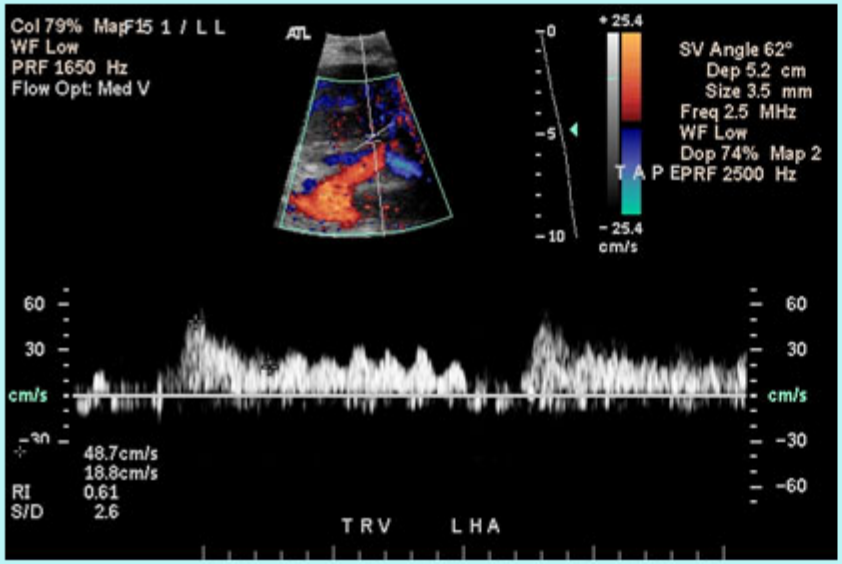

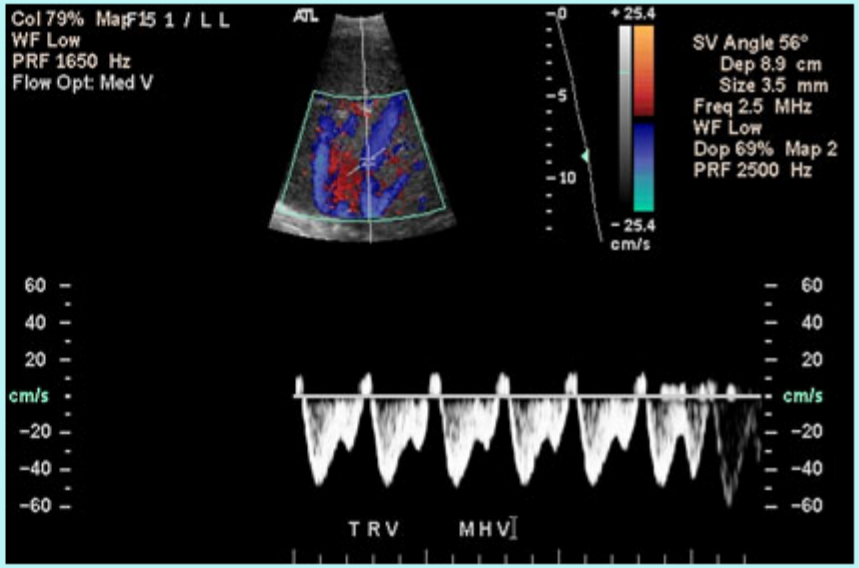

In this transplant recipient, the spectral Doppler waveform (image top left) suggests the presence of rapid antegrade flow in the left hepatic artery. Changing the transducer position (image top right) confirmed that the flow actually arose in the left hepatic vein. No flow could be identified in the left hepatic artery, a finding confirmed on conventional angiography.

Artifactual signal due to IA Balloon Pump (IABP)

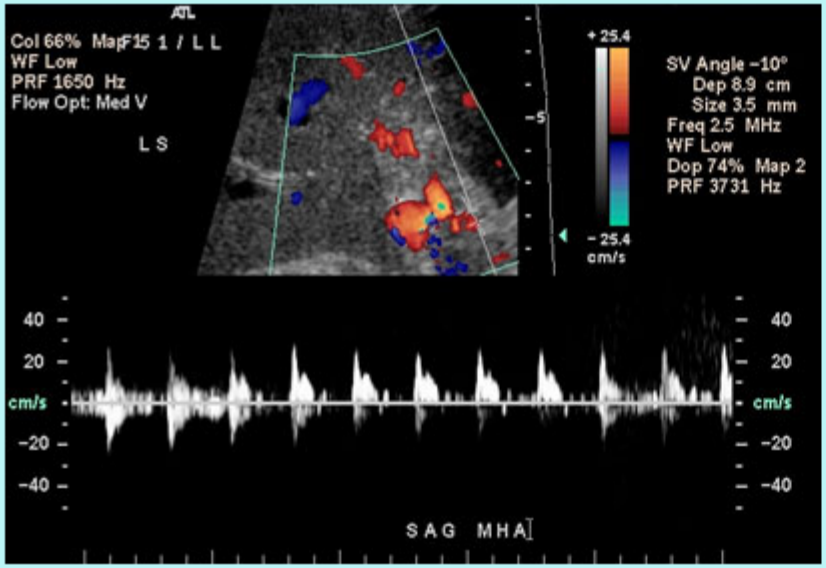

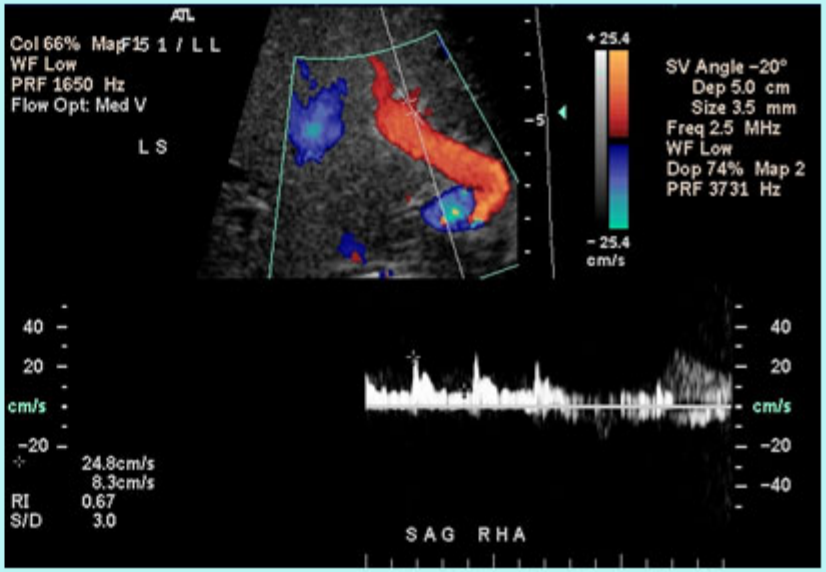

In this POD#2 transplant recipient with an implanted IABP 2 days, regular "systolic" peaks were detected on the spectral Doppler waveform suggesting arterial patency. Note that these peaks extent into the liver and are seen in the expected location of the right hepatic artery (RHA; right image). This is an important pitfall to be aware of since the periodicity of these peaks matches that of the pump setting. *No hepatic artery flow* was identified on CT and conventional catheter angiography.

Dual Hepatic Arterial Anastomosis

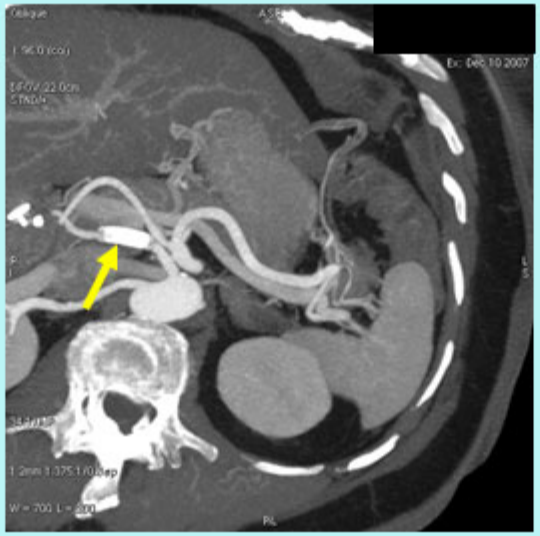

Variant hepatic artery anatomy in the recipient *does* predispose to more complications after liver transplantation (*AJR* 2004; 183:1577-1584).

In donors with replaced left and right hepatic arteries, patency of both hepatic arteries must be confirmed and the spectral waveforms of 2 distinct vessels must be evaluated following grafting. It is essential that flow be characterized in both the left and right intrahepatic arteries as well. These CE-CT scan images show not only that both hepatic arteries are patent post transplant, but that a stent (yellow arrow) has been inserted to maintain patency of the anastomosis of replaced right hepatic artery.

Role of Contrast Microbubbles

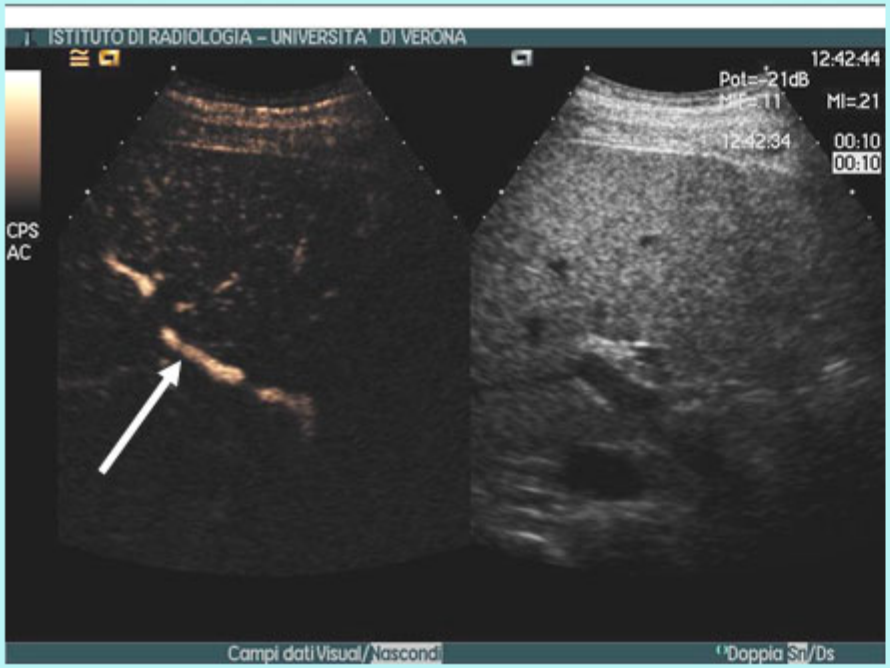

In cases where hepatic arterial flow is difficult to identify or obscured by flow in the adjacent portal vein, contrast microbubbles are very sensitive for detecting the presence of flow in the hepatic artery. This image, acquired prior to the phase of portal vein enhancement, shows normal flow in a patent hepatic artery (arrow).

Comparative studies (*Hom, Liv Transp 2007; 13: 168*) show that contrast microbubbles not only reduce length of study, but are more sensitive than conventional Doppler for detecting HA flow, and reduce unnecessary angiographic procedures (Image courtesy of Giulia Zamboni, MD).

Algorithm for Evaluating the HA

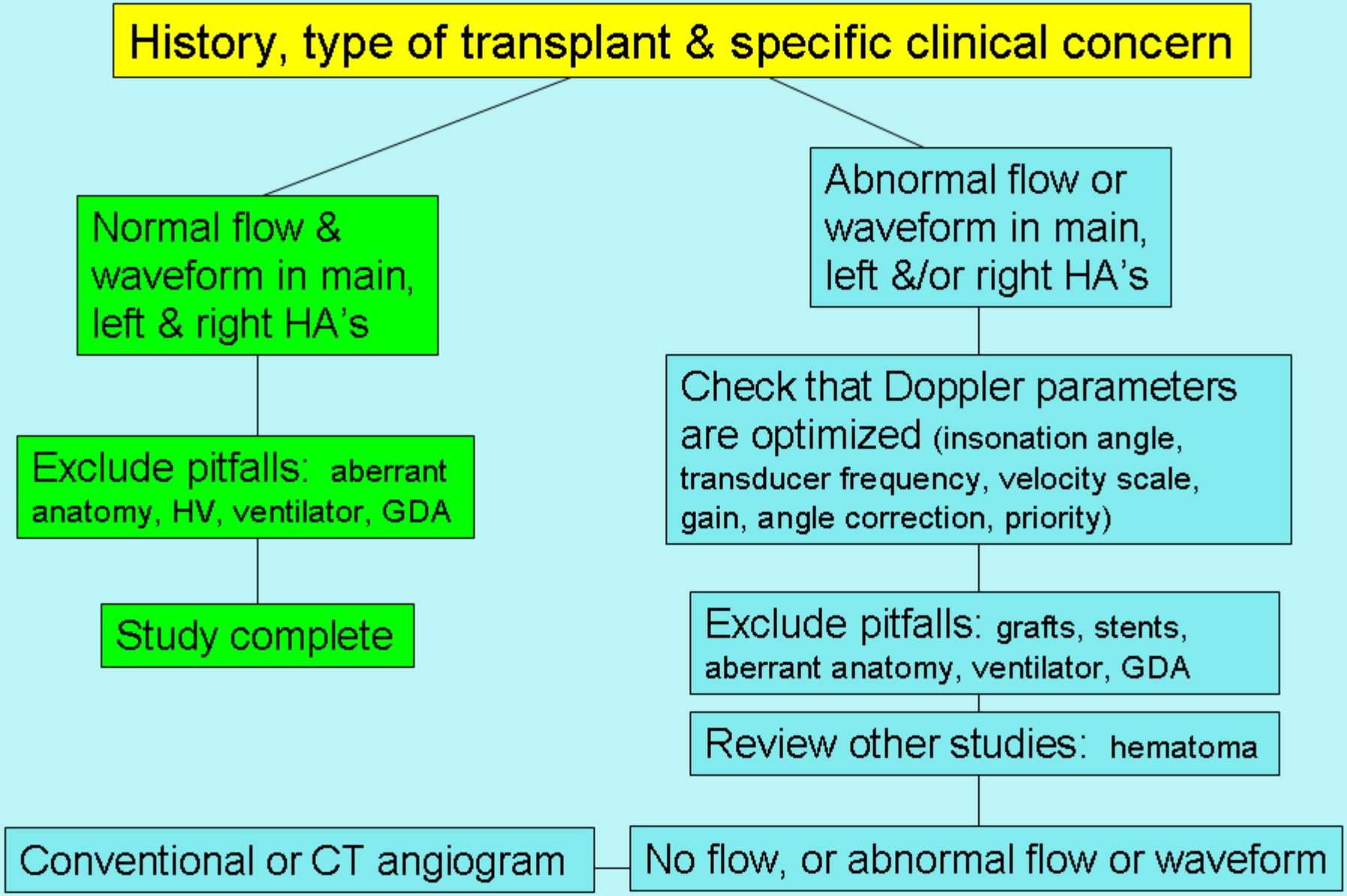

Summary

Hepatic artery flow is essential for normal functioning of the implanted liver; the biliary epithelium is dependent on this arterial blood supply. Ultrasound with Doppler, when properly performed by an experienced operator fully aware of the clinical indications, concerns and imaging pitfalls, is a very useful technique for documenting the presence of and characterizing hepatic arterial flow, and for suggesting the presence of common complications.

The following are recommended reviews on this topic:

1. Crossin J, Muradali D, Wilson SR. US of Liver Transplants: Normal and Abnormal. *RadioGraphics* 2003; 23: 1093-1114.

2. Kruskal JB, Newman PA, Sammons LG, and Kane RA. Optimizing Doppler and Color Flow US: Application to Hepatic Sonography. *RadioGraphics* 2004; 24: 657-675.